

THE LONG STYLOID PROCESS SYNDROME OR EAGLE'S SYNDROME: AN OVERVIEW

FERNANDO DUARTE*; ABEL SALGADO**; JERÓNIMO FERNANDES***

RESUMO

A síndrome de Eagle é uma entidade rara, definida pela presença de um processo estilóide alongado ou pela calcificação do ligamento estilohióideo, que clinicamente passa muitas vezes despercebida. É caracterizada por dor faríngea lenta e persistente acompanhada de dor facial.

Em adição a um exame clínico cuidado, o uso de ortopantomografia e tomografia axial computadorizada permite o correcto diagnóstico pre-operatório desta síndrome. O tratamento cirúrgico tem positivamente resolvido os sintomas na maioria dos casos.

Palavras-chave: Processo estilóide, Eagle, síndrome.

ABSTRACT

Eagle syndrome is a rare entity, defined as an ossification of the styloid process, which is not commonly suspected in clinical practice. Symptoms were dull and persistent pharyngeal pain, dysphagia, and facial pain.

In addition to careful clinical examination, the use of plain radiographs, orthopantomograms or computer tomography scan has allowed accurate preoperative diagnosis of this syndrome. Surgical treatment has positively resolved the symptoms in the majority of the cases.

Key-words: Styloid process, Eagle, syndrome.

INTRODUCTION

In 1652, Pietro Marchetti, a surgeon from Padua, observed an elongation of the styloid process related to an ossifying process of the stylohyoid ligament⁽⁶⁾. However, it was Eagle^(6,8) who first defined stylalgia as an autonomous entity related to abnormal length of the styloid process or to mineralization of the stylohyoid ligament complex. Since then,

several studies have been carried out, although some features of which are still not well explained. In 1988 the Headache Classification Committee of the International Headache Society, even defined the stylohyoid syndrome as "insufficiently demonstrated".

DESCRIPTION

The stylohyoid apparatus (or stylohyoid complex) is made of: styloid process, stylohyoid ligament and the lesser horn of the hyoid bone. Embryologically, these structures are derived from Reichert's cartilage of the second brachial arch. Reichert's cartilage is made of four portions: an upper portion which develops into the styloid process, a central portion from which the stylohyoid ligament is derived; a

*Médico Dentista. Mestre em Cirurgia Oral e Maxilofacial pelo Eastman Dental Institute – Universidade de Londres. Estudante de Doutoramento – Universidade de Londres. Assistente de Cirurgia Oral no I.S.C.S.-N.. Assistente Hospitalar do Serviço de Estomatologia / Medicina Dentária no Hospital Senhora da Oliveira – Guimarães

**Médico Dentista

***Médico e Médico Dentista. Especialista em Cirurgia Geral pela O.M.. Especialista em Cirurgia Oral pela O.M.D. Regente de Cirurgia Oral no I.S.C.S.-N.

lower portion from which the lesser horn of the hyoid bone originates; finally a basic portion from which part of the hyoid bone is formed^(2,14). The styloid process appears as a narrow and elongated protrusion of the temporal bone, directed caudally, medially and anteriorly within the maxillo-vertebro-pharyngeal space, in which important anatomical structures are located such as: both carotid arteries, the internal jugular vein, the facial, glossopharyngeal, vagus and hypoglossal nerves. Here the stylohyoid, the styloglossus and the stylopharyngeus muscles originate (which together form the so-called "Riolano's bouchet") as well as the stylohyoid and stylo-mandibular ligaments (defined as "the bouchet's white flowers"). The stylohyoid muscle originates from the base of the styloid process and is inserting on the hyoid bone near the greater horn. The styloglossus originates close to the apex of the styloid process and from the upper part of the stylo-mandibular ligament and is inserted in the septum of the tongue⁽²²⁾. The stylopharyngeus originates from the medial aspect of the styloid process close to its base and is inserted into the lateral wall of the pharynx. The stylohyoid ligament originates from the apex of the styloid process and is attached inferiorly to the lesser horn of the hyoid bone. The stylo-mandibular ligament originates near the apex of the styloid and is inserted medially into the mandibular angle^(5,11).

Radiologic examinations^(17,21) revealed that the length of the styloid process normally is less than 2.5 cm. However according to other authors⁽²⁰⁾ a "long" styloid process is defined as more than 4 cm, since in this situation the highest incidence of Eagle's syndrome occurs.

INCIDENCE

The incidence of this syndrome varies between populations. Eagle in 1948⁽⁷⁾, found a long styloid process in 4% of the subjects he examined, whereas Kaufman et al.⁽¹⁵⁾ found incidence of 7%. However, just a very low percentage of those had complained of pain⁽²⁶⁾.

This condition is found more often in females

and affects subjects more than 50-years-old most often^(12, 21, 23).

The styloid process originates primarily in the stylole of Reichert's cartilage. It is thought to ossify early in life, at 5 to 8 year of age. The tympanohyal, the uppermost portion of the process, joins with the petrous portion of the temporal bone. However, it remains in a cartilagenous state for a long time, between the process and the temporal bone may be the cause of painful sensations in the throat⁽¹³⁾.

Research has provided histologic evidence for metaplastic changes in the subperiosteal cells in the vicinity of the stylohyoid ligament insertion that ultimately results in the growth of the osseous tissues⁽²⁵⁾.

PATHOGENESIS

Pathogenesis is still being debated. Eagle^(6,8) thought that surgical trauma or local chronic irritation could cause osteitis, periosteitis, or tendonitis of the stylohyoid complex with consequent reactive, ossifying hyperplasia. Later, different hypotheses were formulated such as: persistence of mesenchymal elements able to produce osseous tissue in adults⁽¹⁸⁾; Reichert's cartilage residues undergoing osseous metaplasia as a consequence of trauma or mechanical stress during the development of the styloid process^(16,27); abnormal development associated with malformations of the atlanto-occipital hinge^(1,3); ossification of the stylohyoid ligament related to endocrine disorders in women at the menopause, accompanied by ossification of ligaments elsewhere (iliolumbar, thyrohyoid)⁽⁹⁾.

However, the abnormal length of the styloid process by itself is not sufficient to explain the pathogenesis of Eagle's syndrome, as there is only a low incidence of symptoms. Eagle discovered a close correlation between the manifestation of the classical painful syndrome and tonsillectomy. He felt that this operation was responsible for the formation of scar tissue around the styloid apex in some cases with consequent compression and stretching of the nervous structures contained in the maxillo-

vertebro-pharyngeal space, especially the glossopharyngeal nerve and perivascular carotid sympathetic fibres.

In the original description, Eagle⁽⁶⁾ presented two possible clinical expressions of the syndrome:

- (1) Classical stylohyoid syndrome
- (2) Stylocarotid syndrome

The classical stylohyoid syndrome, almost always following tonsillectomy, is characterized by dull and persistent, pharyngeal pain (pharyngodynia), especially located in the tonsillar fossa, with radiation to the ipsilateral ear, accompanied occasionally by dysphagia and painful swallowing (odynophagia), foreign body sensation, as much as facial and/or cervical pain. Rarely the pain is very intense^(11,28).

The stylocarotid syndrome is not correlated with tonsillectomy. It arises whenever the stylohyoid apparatus compresses the internal and/or external carotid arteries, and especially the perivascular sympathetic fibres. It is characterized by cervical pain arising when the internal carotid artery is compressed, provoked and aggravated by rotation and compression of the neck and radiates to the areas vascularized by the ophthalmic artery with involvement of the supraorbital and parietal regions. In contrast, if the external carotid artery is irritated, the pain radiates to the infraorbital region. Drowsiness and visual disorders can be present. In order to diagnose Eagle's syndrome, it is necessary to obtain an accurate case history. The patient's description of symptoms is important. Even when local examination is negative, the styloid process may be palpated in the tonsillar fossa and this may initiate or aggravate the symptoms. Usually it is not palpable⁽¹¹⁾.

RADIOLOGY

Radiological examination confirms the diagnosis. The diagnosis can be further confirmed with plain radiographs such as the lateral skull film, posteroanterior skull film, oblique mandible films, and Towne's or panoramic

views⁽²⁵⁾. For visualization of the styloid process, orthopantomograms are more advisable than the standard radiological cranial examination with these latter views, identification of the stylohyoid process is not always possible as it is masked by other structures⁽¹⁸⁾.

Computed tomography (CT) is useful to study the anatomic relationships between the elongated bony process and the adjacent vital vascular structures. It is very difficult to ascertain whether the styloid process is elongated or whether the stylohyoid ligament is calcified from radiographic findings alone. Both processes produce radiodensities on plain film radiography and hyperdensities on CT scanning. Clinically, it is difficult to distinguish which of the 2 entities exist, or if there is a coexistence. However, analyzing the specimen for its mineral content may help to distinguish an elongated process from a calcified ligament^(15,25).

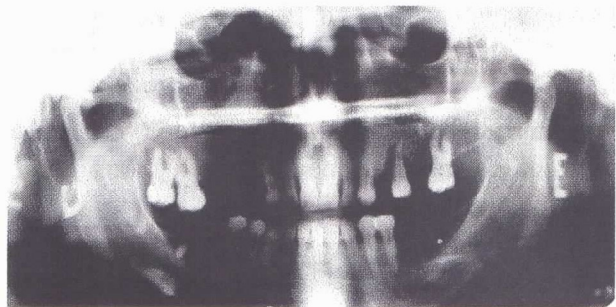


Fig.1 - Ossification of the right styloid process.

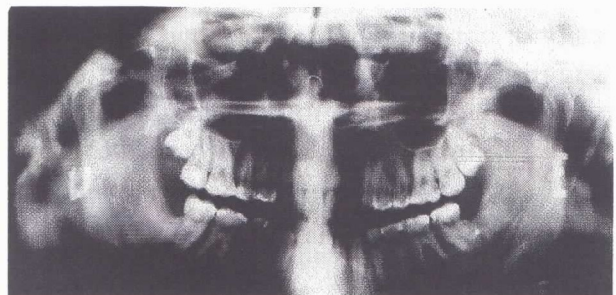


Fig.2 - Ossification of the left styloid process.




Fig.3 - Bilateral ossification of the styloid process.

DIFERENTIAL DIAGNOSIS

The description of a constant, dull pain worsening during swallowing, palpation of the tonsillar fossa and retromandibular area eliciting pharyngeal pain, and a radiologic demonstration of an elongated styloid process should alert the clinician to a possible diagnosis of Eagle's syndrome⁽²⁵⁾.

Several disorders may simulate Eagle's syndrome: the glossopharyngeal and trigeminal neuralgias are characterized by a lancinating and sudden pain of short duration evoked by "trigger zone" stimulation⁽²¹⁾ in contrast to Eagle's syndrome in which pain is dull and persistent. Temporomandibular joint disorders and pain caused by wisdom teeth are confirmed by radiological examination. Carotidynia, which seems to be caused by the pericarotid sympathetic plexus somehow irritated or involved with arteritis manifests with symptoms similar to the stylocarotid syndrome⁽²⁴⁾. The latter presents with hyperpulsation and dilatation of the external and common carotid arteries. Neuralgia of the upper laryngeal nerve, oesophageal diverticula, neoplasia and migraine are also to be considered⁽²⁸⁾.

TREATMENT

Eagle's syndrome can be treated both, surgically or non-surgically. Evans and Clainnont⁽¹⁰⁾ suggested transpharyngeal infiltration of steroidal drugs and local anaesthetics (lidocaine) in the tonsillar fossa whereas Chase et al.⁽⁴⁾ suggest manual fracture of the styloid process although long-term results have not been satisfactory⁽²³⁾.

Styloidectomy is the treatment of choice. It can be performed transorally or by extraoral approach.

The transoral approach was introduced by Eagle. The surgeon locates the styloid process by digital palpation of the tonsillar fossa, followed by surgical incision. Once the styloid process has been identified, it is stripped of the periosteum together with muscles and ligaments. Then styloidectomy is carried out. If the

pharyngeal tonsil is still present, it is necessary to perform tonsillectomy first at the same operation. The advantage of this method is the brevity and the absence of a cervical scar. The disadvantage of the method is the poor visibility leading to major potential risks of iatrogenic injury to the main neurovascular structures. Furthermore, intraoperative contamination is possible⁽¹¹⁾.

The external approach was described by Loeser and Caldwell in 1942⁽¹⁹⁾. A cervical incision is made from the proximal portion of the sternocleidomastoid muscle to the hyoid bone. The parotid fascia is reflected anteriorly, the carotid sheath and the sternocleidomastoid posteriorly. Aponeurotic and muscular insertions are separated from the styloid process which is then dissected and removed. This approach allows adequate visualization of the stylohyoid process and of the nearby structures, and enables greater intraoperative sterility. However, it requires a long recovery and more intervention (drain, sutures) and of course results in a visible neck scar.

After surgery up to 20% of the patients may have a recurrence of symptoms⁽²⁹⁾. Surgical intervention carries a risk to the carotid arteries and various cranial nerves. Surgery should be reserved for patients with symptoms unresponsive to all conservative measures⁽²⁹⁾.

Implementation of conservative and noninvasive treatments, including education, behavioral training, and pain or stress management, may reduce symptoms to a degree that further intervention is unnecessary⁽²⁹⁾.

CONCLUSIONS

We think that not only a long stylohyoid process, but also other factors are necessary to give rise to Eagle's syndrome.

CT scan is best for diagnosis, although an accurate case history as well as the specialist's intuition are fundamentally important for the differential diagnosis regarding several other pharyngo-cranial-facial pain disorders.

In our opinion, surgical treatment is the first choice and the transoral approach is preferable.

This approach, avoiding injury to important structures contained in the maxilo-vertebro-pharyngeal space, is characterized by a short operation, and absence of visible scars as well as reduced hospitalisation issue.

REFERENCES

- 1- Arnould G: Appareil stylo-hyoidien et malformations de la chamiere occipito-vertebrale. *Rev Otoneuroophthalmol* 41:190-195, 1969
- 2- Barrett AW, Griffiths MJ, Scully C: Osteoarthritis, the temporomandibular joint, and Eagle's syndrome. *Oral Surg Oral Med Oral Pathol* 75(3):273-275, 1993
- 3- Carrella A: Apparato stilo-ioideo e malformazione della cerniera atlo-occipitale. *Acta Neurol Napol* 26:466-472, 1971
- 4- Chase DC, Zarman A, Bigelow WC, McCoy JM: Eagle's syndrome: a comparison of intraoral versus extraoral surgical approaches. *Oral Surg* 62:625-629, 1986
- 5- Correl R, Jensen J, Taylor J, Rhyne R: Mineralization of the stylohyoid-stylomandibular ligament complex: A radiographic incidence study. *Oral Surg Oral Med Oral Pathol* 48:286-291, 1979
- 6- Eagle W: Elongated styloid process. Report of two cases. *Arch Otolaryngol* 25:584-587, 1937
- 7- Eagle W: Elongated styloid process: Further observation and a new syndrome. *Arch Otolaryngol* 47:630-640, 1948
- 8- Eagle W: Symptomatic elongated styloid process: Report of two cases of styloid process-carotid artery syndrome with operation. *Arch Otolaryngol* 49:490-493, 1949
- 9- Epifanio G: Processi stiloidei lunghi e ossificazione della catena stiloidea. *Rad Prat* 12:127-132, 1962
- 10- Evans JT, Clainnot AA: The nonsurgical treatment of Eagle's syndrome. *Ear Nose Throat J* 55:44-45, 1976
- 11- Fini G, Gasparini G, Filippini F, Becelli R, Marcotullio D: The long styloid process syndrome or Eagle's syndrome. *J Craniomaxillofac Surg* 28:123-127, 2000
- 12- Glogoff MR, Gavan SM, Chiefetz J: Diagnosis and treatment of Eagle's syndrome. *J Oral Surg* 39:941-944, 1981
- 13- Godden DRP, Adam S, Woodward RTM: Eagle's syndrome: an unusual cause of a clicking jaw. *Br Dent J* 186:489-490, 1998
- 14- Guerrier Y, Rabischong P, Guerrier B: Cours superieur d'anatomie chirurgicale de cou et des glandes salivaires. Ed. Lib. Arnett, Montpellier, 1988
- 15- Kaufman SM, Elzay RP, Irish EF: Styloid process variation: Radiologic and clinical study. *Arch Otolaryngol* 91:460-463, 1970
- 16- Laino G, Ammirati G, Serpico S: Styloid-stylohyoid syndrome or Eagle's syndrome. *Arch Stomatol* 28:183-190, 1987
- 17- Langlais R, Miles DA, Van Dis ML: Elongated and mineralized stylohyoid ligament complex: a proposed classification and report of a case of Eagle's syndrome. *Oral Surg* 61:527-532, 1986
- 18- Lentini A: Gli aspetti clinici e radiologici delle anomalie dell'apparato stilo-joideo. *Radiol Med* 61:337-364, 1975
- 19- Loeser L, Caldwell E: Elongated styloid process: a cause of glossopharyngeal neuralgia. *Arch Otolaryngol* 36:198-202, 1942
- 20- Monsour P, Young WJ: Variability of the styloid process and stylohyoid ligament in panoramic radiographs. *Arch Otolaryngol* 61:522-526, 1986
- 21- Montalbetti L, Ferrandi D, Pergami P, Savoldi F: Elongated styloid process and Eagle's syndrome. *Cephalalgia* 15:80-93, 1995
- 22- Motta P, Renda T, Marinozzi G: Anatomia Umana. Edi Ermes, Milano, 11:209-216, 1987
- 23- Murthy PSN, Hazarika P, Mathai M, Kumar A, Kamatah MP: Elongated styloid process: an overview. *Int J Maxillofac Surg* 19:230-231, 1990
- 24- Prendes J: Carotidynia or Eagle's syndrome? *Headache* 26:26-46, 1983
- 25- Quereshy FA, Gold ES, Arnold J, Powers MP: Eagle's syndrome in an 11-year-old patient. *J Oral Maxillofac Surg* 59:94-97, 2001
- 26- Rizzatti-Barbosa CM, Lopes EB, Albergaria-Barbosa JR, Gomes BP: Eagle's syndrome associated with temporomandibular disorder: A clinical report. *J Prosthet Dent* 81(6):649-651, 1999
- 27- Roca A, Armengton M, Gimenez G, Barona R, Basterra J: tratamiento quirurgico del syndrome de Eagle por via orofarigea. A proposito de un caso. *Acta Otorrinolaring Esp* 43:210-212, 1992
- 28- Van der Westhuyzen AJ, van der Merwe J, Grotepass FW: Eagle's syndrome: lesser cornu amputation: an alternative surgical solution? *Int J Oral Maxillofac Surg* 28:335-337, 1999
- 29- Zaki HS, Greco CM, Rudy TE, Kubinski JA: Elongated styloid process in a temporomandibular disorder sample: Prevalence and treatment outcome. *J Prosthet Dent* 75(4):399-405, 1996