

Graft-Less Solution for Extreme Atrophic Maxilla: Zygomatic and Short Implants Combined - Case Series

Fernando Duarte^{1*}, Luis Pinheiro², Carina Ramos³ and João Neves Silva¹

¹Professor at Instituto Superior de Saúde, ISAVE, Portugal

²Clinical Director of Cero, Lisbon, Portugal

³MSc Student in Oral Oncology at Instituto de Ciências Biomédicas Abel Salazar, Oporto University, Portugal

*Corresponding Author: Fernando Duarte, Professor at Instituto Superior de Saúde, ISAVE, Portugal.

Received: June 15, 2020; Published: June 30, 2020

Abstract

Background: Zygomatic implants have been in use since the 1990's for the treatment of patients with severely resorbed posterior maxilla. In the anterior premaxilla the viability and high success rate seen with short implants reinforce their choice. The combination of these two implants solutions may allow eliminating grafting and immediate function.

Purpose: The purpose of this study was to evaluate a protocol for immediate function with fixed prostheses for patients with extreme maxillary atrophy, treated with two zygomatic implants (S.I.N.-Implant System, São Paulo, Brazil) combined with 2 short implants (S.I.N.-Implant System, São Paulo, Brazil).

Materials and Methods: This prospective clinical study included 12 patients with 48 immediately loaded implants (24 zygomatic implants and 24 short implants) with fixed provisional acrylic prosthesis attached 5 to 6 hours after surgery.

Results: The patients' follow-up was from 12 to 60 months. Two short implants failed (implant survival rate 92%), none of the zygomatic implants failed (implant survival rate 100%). There were no complications such as sinusitis, hygiene maintenance or speech impairment.

Discussion: The results support the hypothesis that immediate function with two zygomatic implants combined with two short implants is a viable concept. The clinical success for these patients was enhanced by the shorter time span of the treatment process and the immediate rehabilitation in a comfortable manner as compared to grafting based procedures.

Conclusion: The high survival rate, the increase of patients' demand in immediate functional ability and the less morbidity following the surgical procedure renders this immediate function procedure a viable treatment option of the resorbed fully edentulous maxilla.

Keywords: Zygomatic Implant; Short Implant; Edentulous Maxilla; Atrophic Maxilla; Immediate Function

Introduction

Zygomatic implants have shown good clinical success rates in clinical studies, most often close to 100% success with follow-up periods of up to 5 years [1-4]. In review of literature from 2004, Brånemark and colleagues reported cumulative survival rate (CSR) of 94,2% on a 5 to 10-year follow up and in more recent study, Bedrossian observed a CSR of 97,2% [5]. Sinuscopy performed in patients with zygomatic implants showed no signs of infection or inflammation in the surrounding mucosa [6]. The original concept featured a single implant in the zygoma bilaterally, combined with 2 to 4 conventional implants in the anterior maxilla. Although the method has proved to be predictable, bone grafting to the region below the nasal aperture is sometimes required prior to implant placement [7-11]. In an effort to provide a graft-free procedure for patients with atrophic maxillae and very severe bone resorption in the anterior maxilla, a modified technique utilizing two zygomatic

implants anchored in the zygoma bone combined with two short implants in the premaxilla is presented.

Immediate function, a well-documented concept [12-15], where implants are immediately loaded after insertion has shown high success rates, provided high primary stability [16]. Histological analysis of the zygoma bone shows regular trabeculae and compact bone with an osseous density of up to 98% [17]. Due to this high bone density [17] and the high documented clinical success rates for zygomatic implants [1,4] it can be anticipated that this bone is suitable for immediate function.

The use of short implants offers, in relation to the regenerative techniques, several advantages: low cost and treatment length, simplicity, and less risk of complications [18,19]. Short implants are easier to place in clinical sites with healthy bone, albeit with lower height and volume than required for longer implants. They

have been studied in single unit and multiple-unit implant-supported fixed prostheses and overdentures. In recent studies, they have proven to have success and survival rates equivalent to longer implants [18,19].

Objective of the Study

The objective of the current study was to test the hypothesis that the protocol using two zygomatic implants combined with two short implants in patients with extreme maxillary atrophy may be considered as a rehabilitation alternative.

Materials and Methods

The study was based on 12 patients treated at Clitrofa - Centro Médico, Dentário e Cirúrgico Lda. (Trofa - Portugal), by one and

the same team, between January 2017 and January 2020, provided they met the inclusion criteria and gave their written consent to the procedure. The patients had two zygomatic implants (S.I.N.-Implant System, São Paulo, Brazil) placed bilaterally, combined with two short implants placed in the pre-maxilla (S.I.N.-Implant System, São Paulo, Brazil). All implants were rehabilitated with straight abutments (S.I.N.-Implant System, São Paulo, Brazil). The patients were 8 women and 4 men, the average age for the women being 61 ± 9 years and for the men 59 ± 14 years. All the patients were non-smokers. Details of implant and abutment dimension per position and types of opposing jaws are shown in table 1.

Inclusion criteria

The inclusion criteria for the treatment were: i) need for complete rehabilitation of the edentulous maxilla; ii) no possibility for

Case	Age	Sex	Implant Length (mm)				Antagonist occlusion
			1 st QS	1 st QZ	2 nd QS	2 nd QZ	
1	71	M	5 mm	35 mm	5 mm	35 mm	Natural Teeth
Abutment Type			3 mm	3 mm	3 mm	3 mm	
2	58	F	5 mm	35 mm	5 mm	35 mm	Total Implant-supported Rehab
Abutment Type			3 mm	3 mm	3 mm	3 mm	
3	49	F	5 mm	47.5 mm	5 mm	45 mm	Natural Teeth
Abutment Type			3 mm	3 mm	3 mm	3 mm	
4	78	F	5 mm	50 mm	5 mm	47.5 mm	Natural Teeth
Abutment Type			3 mm	3 mm	3 mm	3 mm	
5	66	F	6 mm	35 mm	5 mm	35 mm	Natural Teeth
Abutment Type			3 mm	3 mm	3 mm	3 mm	
6	54	F	6 mm	32.5 mm	6 mm	32.5 mm	Acrylic Prosthesis
Abutment Type			3 mm	3 mm	3 mm	3 mm	
7	61	F	5 mm	40 mm	6 mm	40 mm	Total Implant-supported Rehab.
Abutment Type			3 mm	3 mm	3 mm	3 mm	
8	42	M	6 mm	37.5 mm	5 mm	40 mm	Overdenture
Abutment Type			3 mm	3 mm	3 mm	3 mm	
9	70	M	5 mm	32.5 mm	5 mm	32.5 mm	Natural Teeth
Abutment Type			3 mm	3 mm	3 mm	3 mm	
10	62	F	5 mm	40 mm	5 mm	40 mm	Total Implant-supported Rehab.
Abutment Type			3 mm	3 mm	3 mm	3 mm	
11	57	F	5 mm	35 mm	5 mm	35 mm	Natural Teeth
Abutment Type			3 mm	3 mm	3 mm	3 mm	
12	53	M	.5 mm	35 mm	5 mm	35 mm	Natural Teeth
Abutment Type			3 mm	3 mm	3 mm	3 mm	

Table 1: Distribution of the zygomatic and short implants in immediate function.

1stQS - First Quadrant Short Implant. 1stQZ - First Quadrant Zygoma Implant. 2ndQS - Second Quadrant Short Implant.

2ndQZ - Second Quadrant Zygoma Implant.

insertion of 5 - 6 standard implants in the anterior region of the maxilla; iii) a posterior bone height of less than 5 mm; iv) psychological motivation to be treated.

Surgical and prosthetic procedure

The pre-surgical radiographic evaluation included panoramic radiographs and CT scans which has been used previously [20-22]. To identify the anatomic structures and detect any presence of pathology at the 3 levels to investigate: the maxilla, the sinus and the zygoma bone. Preoperative considerations should also involve shape of the face, degree of resorption, maxillo-mandibular jaw relationship and patient expectations. A narrow face will be unfavourable as far as intraoperative access and implant inclination are concerned. An edentulous mandible will facilitate access.

A palatal 45° incision along the entire maxillary crest, combined with a full thickness flap from maxillary crest to zygoma buttress and the suborbital nerve identification are the first steps to this surgery [23,24]. In order to determine the orientation of the zygomatic implant and to reflect the Schneiderian membrane, a window was made by cutting at the upper limit between the zygoma bone and the sinus using a piezoelectric device. This window was also helpful during the surgical procedure for cooling the drills to avoid overheating [13,20,25]. In patients with existing implant-supported prostheses in the mandible, the prosthesis should be removed prior to the surgery.

Different drills were used with increasing diameters, ending with the insertion at low speed of the self-tapping zygomatic implant. The implant length was chosen by means of a gauge and can go from 32.5 mm to 62.5 mm.

In consideration to short implants, a milling system was specifically developed for their use, with a drilling rotation of 800 RPM. The implant was installed on bone level in a rotation from 15 to 25 RPM. The implant length can go from 4 mm to 6 mm.

After insertion of the implants, the abutments were placed on the top of the zygomatic and short implants, the soft tissue closed and an immediate (5 - 6 hours after) provisional acrylic prosthesis reinforced by a metal strip, was provided for the patient. Final prostheses were placed after 5 - 6 months [26-28].

Survival criteria

An implant was classified as surviving if it fulfilled its purported function and was stable when tested individually after the removal

of the prosthesis. Lack of gross mobility as well as the absence of pain upon percussion along with no sign of peri-implant pathology further determined the survivability of the implants.

Follow-up

The patients were followed-up and the implants were checked for survival after 3 and 6 months and then once a year. It was not possible to judge the marginal bone change at the zygomatic implants as their placement orients the implant platform slightly palatal to the crest, superimposing the marginal bone over the implant. Orthopantomograms were done on all the patients after provisional and definitive prosthesis insertion and a tomography at 12 months follow-up. All patients were followed-up according to plan and no dropout occurred.

Results

Follow-up of the patients from 12 to 60 months revealed no clinical symptoms but 2 of 24 short implants failed (implant survival rate 92%) (Table 2), none of the 24 zygomatic implants failed (implant survival rate 100%) (Table 3).

Duration	Number of Implants					CSR
	Total	Successful	Failed	With drawn	Not yet due	
Placement - 6 months	0	6	0	0	0	100,0%
1 months - 1 year	0	6	0	0	0	100,0%
1 - 2 years	---	6	0	0	0	100,0%
2 - 3 years	---	2	0	0	0	100,0%
3 - 5 years	---	4	0	0	0	100,0%

Table 2: Life table analysis zygomatic implants.
CSR: Cumulative Survival Rate.

Duration	Number of Implants					CSR
	Total	Successful	Failed	With-drawn	Not yet due	
Placement - 6 months	0	6	0	0	0	100,0%
1 months - 1 year	0	6	0	0	0	100,0%
1 - 2 years	---	6	1	0	0	100,0%
2 - 3 years	---	2	0	0	0	100,0%
3 - 5 years	---	4	1	0	0	100,0%

Table 3: Life table analysis short implants.
CSR: Cumulative Survival Rate.

During surgery, the sinus membrane was perforated in all the cases; however, there were no important postoperative complications. In all cases substantial benefit in terms of oral function was obtained, and all patients reported improvement in self-esteem and social relations. To make dental implant treatment a pleasant experience for every patient is not easy, but it should be our objective to make it more acceptable and more comfortable for our patients [29].

Complications

Two infective complications were detected in 2 patients who lost one implant each; in both cases the implant lost was the first quadrant anterior short implant.

A third complication was detected in 2 patients who presented a severe infection of the maxillary sinus, which was successfully treated with antibiotics. Zygomatic implant placement appears to be a predictable procedure without serious maxillary sinus complications [30].

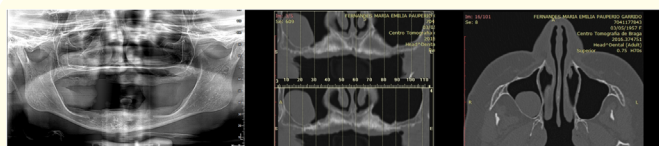


Figure 1: Pre-operative imagiological protocol included panoramic radiographs and CT scans.

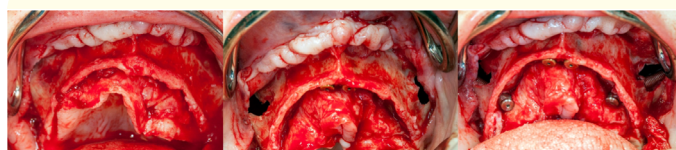

Figure 2: Intraoperative image showing the zygomatic and short implants in position.

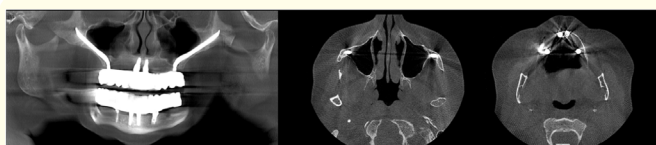


Figure 3: Post-operative imagiological protocol included panoramic radiographs and CT scans.

Discussion

The results attained, supports the hypothesis that immediate function with two zygomatic implants combined with two short implants is a viable concept. The high survival rate of the zygomatic implants mimics that of the 2-stage protocol [31,32] and it can be hypothesized that the dense bone structure of the zygoma bone is a contributing factor for this good outcome.

Concern about primary stability and careful patient selection are the possible reasons for these high survival rates as the oral rehabilitation when zygomatic implants are involved, usually uses a prosthetic connection of all maxillary implants with a rigid connector will result in a better distribution and sharing of the occlusal loading [33].

Short implants result in the removal of less bone than with longer implants and are less invasive compared to these and therefore probably less traumatic. Short implants simplify treatment in the anterior resorbed maxilla and reduce the number of situations where adjunctive therapy is required. Even in cases where adjunctive therapy is still required, the degree of invasiveness may be reduced, they also remove the need for cantilevers that might otherwise be required to avoid placing implants in an area with resorbed bone and that are associated with a higher failure rate [34].

The clinical success for these patients was enhanced by the shorter time span of the treatment process. This technique allows the reduction in the total treatment time by eliminating the months usually required for bone grafts to mature before performing implants and eliminates the necessity of additional healing time required for implants [9,35-37]. As a consequence, the patients get immediate rehabilitation in a comfortable manner as compared to the grafting based procedures.

Furthermore, there are other benefits for patients subjected to this graftless treatment, such as improvement in self-esteem and social relationships which has been observed in the current study and by others [38].

Conclusion

The presence of sufficient bone volumes is one of the most important variables for successful oral osteointegration of implants [39], wherefore restoration of atrophied edentulous maxilla poses a great dilemma for the surgeon and restorative dentist. Sinus bone grafting to build new bone for implant anchorage in atrophied jaws

entail multiple surgical interventions, varying success rates of the implants, potential for donor site morbidity as well as increased surgical fees [40,41].

Zygomatic implants combined with short implants technique may allow the surgical rehabilitation of patients presenting with severe maxillary resorption, providing a valid alternative with excellent support to dental rehabilitation either functionally either aesthetically.

Bibliography

1. Malevez C, Abarca M, Durdu F, Daelemans P. Clinical outcome of 103 consecutive zygomatic implants: a 6-48 months follow-up study. *Clin Oral Implants Res* 2004;15:18-22.
2. Patel RR, Brook MI, Wragg PF. Zygoma implants or sinus augmentation and conventional implants? *Clin Oral Implants Res*. 2003;14.
3. Stevenson AR, Austin BW. Zygomatic fixtures--the Sydney experience. *Ann R Australas Coll Dent Surg*. 2000;15:337-339.
4. Branemark PI, Grondahl K, Ohnrell LO, Nilsson P, Petruson B, Svensson B, Engstrand P, Nannmark U. Zygoma fixture in the management of advanced atrophy of the maxilla: technique and long-term results. *Scand J Plast Reconstr Surg Hand Surg*. 2004;38:70-85.
5. Bedrossian E. Rescue Implant Concept: The Expanded Use of the Zygo Implant in the Graftless Solutions. *Dent Clin N Am*. 2011;55:745-777.
6. Hirsch JM, Ohnrell LO, Henry PJ, Andreasson L, Branemark PI, Chiapasco M, Gynther G, Finne K, Higuchi KW, Isaksson S, Kahnberg KE, Malevez C, Neukam FW, Sevetz E, Urgell JP, Widmark G, Bolind P. A clinical evaluation of the Zygo fixture: one year of follow-up at 16 clinics. *J Oral Maxillofac Surg*. 2004;62:22-29.
7. Weischer T, Schettler D, Mohr C. Titanium implants in the zygoma as retaining elements after hemimaxillectomy. *Int J Oral Maxillofac Implants*. 1997;12:211-214.
8. Tamura H, Sasaki K, Watahiki R. Primary insertion of implants in the zygomatic bone following subtotal maxillectomy. *Bull Tokyo Dent Coll*. 2000;41:21-24.
9. Balshi TJ, Wolfinger GJ. Treatment of congenital ectodermal dysplasia with zygomatic implants: a case report. *Int J Oral Maxillofac Implants*. 2002;17:277-281.
10. Penarrocha-Diago M, Uribe-Origone R, Rambla-Ferrer J, Guarinos-Carbo J. Fixed rehabilitation of a patient with hypohidrotic ectodermal dysplasia using zygomatic implants. *Oral Surg Oral Med Oral Pathol Oral Radiol Endod*. 2004;98:161-165.
11. Penarrocha-Diago M, Uribe-Origone R, Guarinos-Carbo J. Implant-supported rehabilitation of the severely atrophic maxilla: a clinical report. *J Prosthodont*. 2004;13:187-191.
12. Balshi TJ, Wolfinger GJ. Teeth in a day for the maxilla and mandible: case report. *Clin Implant Dent Relat Res*. 2003;5:11-16.
13. Balshi TJ, Wolfinger GJ. Immediate loading of dental implants in the edentulous maxilla: case study of a unique protocol. *Int J Periodontics Restorative Dent*. 2003;23:37-45.
14. Nakai H, Okazaki Y, Ueda M. Clinical application of zygomatic implants for rehabilitation of the severely resorbed maxilla: a clinical report. *Int J Oral Maxillofac Implants*. 2003;18:566-570.
15. Salinas TJ. Extended-length implants for reconstruction of the edentulous-maxilla. *Pract Proced Aesthet Dent*. 2001;13:608.
16. Balshi SF, Wolfinger GJ, Balshi TJ. Analysis of 164 titanium oxide-surface implants in completely edentulous arches for fixed prosthesis anchorage using the pterygomaxillary region. *Int J Oral Maxillofac Implants*. 2005;20:946-952.
17. Gosain AK, Song L, Capel CC, Corrao MA, Lim TH. Biomechanical and histologic alteration of facial recipient bone after reconstruction with autogenous bone grafts and alloplastic implants: a 1-year study. *Plast Reconstr Surg*. 1998;101:1561-1571.
18. Abu-Hussein M, Watted N, Shamir D. A Retrospective Study of the AL Technology Implant System used for Single-Tooth Replacement. *Int J Oral Craniofac Sci*. 2016;2(1):39-46.
19. Abu-Hussein M, Georges C, Watted N, Azzaldeen A ;A Clinical Study Resonance Frequency Analysis of Stability during the Healing Period. *Int J Oral Craniofac Sci*. 2016;2(1):65-71.
20. Malevez C, Daelemans P, Adriaenssens P, Durdu F. Use of zygomatic implants to deal with resorbed posterior maxillae. *Periodontol* 2000. 2003;33:82-89.
21. Vrielinck L, Politis C, Schepers S, Pauwels M, Naert I. Image-based planning and clinical validation of zygo and pterygoid implant placement in patients with severe bone atrophy using customized drill guides. Preliminary results from a prospective clinical follow-up study. *Int J Oral Maxillofac Surg*. 2003;32:7-14.

22. Van Steenberghe D, Malevez C, Van Cleynenbreugel J, Serhal CB, Dhoore E, Schutyser F, Suetens P, Jacobs R. Accuracy of drilling guides for transfer from three-dimensional CT-based planning to placement of zygoma implants in human cadavers. *Clin Oral Implants Res.* 2003;14:131-136.
23. Boyes-Varley JG, Howes DG, Lownie JF, Blackbeard GA. Surgical modifications to the Branemark zygomaticus protocol in the treatment of the severely resorbed maxilla: a clinical report. *Int J Oral Maxillofac Implants.* 2003;18:232-237.
24. Boyes-Varley JG, Howes DG, Lownie JF. The zygomaticus implant protocol in the treatment of the severely resorbed maxilla. *SADJ.* 2003;58:106-109, 113-114.
25. Stella JP, Warner MR. Sinus slot technique for simplification and improved orientation of zygomaticus dental implants: a technical note. *Int J Oral Maxillofac Implants.* 2000;15:889-893.
26. Al-Nawas B, Wegener J, Bender C, Wagner W. Critical soft tissue parameters of the zygomatic implant. *J Clin Periodontol.* 2004;31:497-500.
27. Landes CA. Zygoma implant-supported midfacial prosthetic rehabilitation: a 4-year follow-up study including assessment of quality of life. *Clin Oral Implants Res.* 2005;16:313-325.
28. Bedrossian E, Rangert B, Stumpel L, Indersano T. Immediate function with the Zygoma implant - A graft-less solution for the patient with mild to advanced atrophy of the maxilla. *Int J Oral Maxillofac Implants.* 2006;21(6):937-942.
29. Chow J, Lee M, Li W. Zygomatic Implants - Protocol for Immediate Occlusal Loading: A Preliminary Report. *J Oral Maxillofac Surg.* 2006;64:804-811.
30. D'Agostino L, Favero V, Pessina M, Procacci P, Nocini PF. Are Zygomatic Implants Associated With Maxillary Sinusitis? *J Oral Maxillofac Surg.* 2016;74:1552-1573.
31. Bedrossian E, Stumpel L, 3rd, Beckely ML, Indresano T. The zygomatic implant: preliminary data on treatment of severely resorbed maxillae. A clinical report. *Int J Oral Maxillofac Implants.* 2002;17:861-865.
32. Malevez C, Abarca M, Durdu F, Daelemans P. Clinical outcome of 103 consecutive zygomatic implants: a 6-48 months follow-up study. *Clin Oral Implants Res.* 2004;15:18-22.
33. Chrcanovic R, Wennerberg A. Survival and Complications of Zygomatic Implants: An Updated Systematic Review. *J Oral Maxillofac Surg.* 2016;74:1949-1964.
34. Ferrigno N, Laureti M, Fanali S. Inferior alveolar nerve transposition in conjunction with implant placement. *Int J Oral Maxillofac Implants.* 2005;20(4):610-620.
35. Bedrossian E, Stumpel LJ. Immediate stabilization at stage II of zygomatic implants: rationale and technique. *J Prosthet Dent.* 2001;86:10-14.
36. Ferrara ED, Stella JP. Restoration of the edentulous maxilla: the case for the zygomatic implants. *J Oral Maxillofac Surg.* 2004;62:1418-1422.
37. Pham AV, Abarca M, De Mey A, Malevez C. Rehabilitation of a patient with cleft lip and palate with an extremely edentulous atrophied posterior maxilla using zygomatic implants: case report. *Cleft Palate Craniofac J.* 2004;41:571-574.
38. Penarrocha M, Uribe R, Garcia B, Marti E. Zygomatic implants using the sinus slot technique: clinical report of a patient series. *Int J Oral Maxillofac Implants.* 2005;20:788-792.
39. Higuchi KW. The zygomaticus fixture: an alternative approach for implant anchorage in the posterior maxilla. *Ann R Australas Coll Dent Surg.* 2000;15:28-33.
40. Malevez C, Daelemans P, Adriaenssens P, Durdu F. Use of zygomatic implants to deal with resorbed posterior maxillae. *Periodontol 2000.* 2003;33:82-89.
41. Jensen O, Rangert B, Aparicio C, Malevez C, Bedrossian E, Renouard F, Maló P, Calandiello R. *The Sinus Bone Graft.* Quintessence Publishing Co, Inc, 2006.

Volume 3 Issue 7 July 2020

© All rights are reserved by Fernando Duarte., et al.