

Dynamic navigation and technical improvements in zygomatic surgery

Navegação dinâmica e melhorias técnicas em cirurgia zigomática

Navegación dinámica y mejoras técnicas en cirugía cigomática

Fernando Manuel Pinto Duarte¹

Patrícia Carina da Silva Assunção Ramos²

João Paulo Neves da Silva³

Luís Miguel de Lemos Pinheiro⁴

Simão Pedro Pereira da Silva⁵

1 fduarte@clitrofa.com

2 cramos@clitrofa.com

3 joao.neves@isave.pt

4 luis.pinheiro.16@ucl.ac.uk

5 enf.simaosilva@gmail.com

Endereço para correspondência:

Fernando Manuel Pinto Duarte
Clitrofa - Centro Médico, Dentário e Cirúrgico
Avenida de Paradela 626, 4785-342
Trofa - Portugal
E-mail: fduarte@clitrofa.com

Recebido: 02.09.2020

Aceito: 11.09.2020

ABSTRACT

The rehabilitation of the severely atrophied edentulous maxilla poses a great challenge to surgeons and prosthodontics that work on this particular area. The classic approach implies bone augmentation techniques by means of bone grafting, bone distraction techniques, tilted and short implants. All of these require major surgery, sometimes associated with morbidity at donor and receptor sites and functional rehabilitation of the patient must occur in two surgical stages. Since the development of the zygomatic implants by Per-Ingvar Branemark, there's an alternative to bone grafting techniques, using the body of the zygomatic bone as major point of anchorage to an intraoral osteointegrated implant. This procedure allows the patient to regain orofacial function in only one surgical stage, with high predictability, less morbidity, time spend and costs. In this scientific article the authors present a set of technical improvements in the zygomatic implant (S.I.N. - Implant System, São Paulo, Brazil) in combination with a new dynamic navigation system called StealthStation™ (Medtronic, Dublin, Ireland) used for the first time in this type of surgery.

KEYWORDS: Dental implants. Zygoma. Maxilla

RESUMO

A reabilitação da maxila edêntula gravemente atrofiada representa um grande desafio para os cirurgiões e próteses que atuam nesta área em particular. A abordagem clássica envolve técnicas de aumento ósseo por meio de enxerto ósseo, técnicas de distração óssea, implantes inclinados e curtos. Todos eles requerem cirurgia de grande porte, às vezes associada à morbidade nos sítios doadores e receptores, e a reabilitação funcional do paciente deve ocorrer em dois estágios cirúrgicos. Desde o desenvolvimento dos implantes zigomáticos por Per-Ingvar Branemark, existe uma alternativa às técnicas de enxerto ósseo, utilizando o corpo do osso zigomático como principal ponto de ancoragem para um implante intraoral osteointegrado. Esse procedimento permite que o paciente recupere a função orofacial em apenas uma etapa cirúrgica, com alta previsibilidade, menor morbidade, tempo gasto e custos. Neste artigo científico os autores apresentam um conjunto de melhorias técnicas no implante zigomático (S.I.N. - Implant System, São Paulo, Brasil) em combinação com um novo sistema de navegação dinâmica denominado StealthStation™ (Medtronic, Dublin, Irlanda) usado pela primeira vez neste tipo de cirurgia.

PALAVRAS-CHAVE: Implantes dentários. Zigoma. Maxila.

RESUMEN

La rehabilitación del maxilar edéntulo severamente atrofiado representa un gran desafío para los cirujanos y los protésicos que trabajan en esta área en particular. El abordaje clásico implica técnicas de aumento óseo mediante injertos óseos, técnicas de distracción ósea, implantes inclinados y cortos. Todos ellos requieren una cirugía mayor, a veces asociada con morbilidad en los sitios donantes y receptores, y la rehabilitación funcional del paciente debe ocurrir en dos etapas quirúrgicas. Desde el desarrollo de los implantes cigomáticos por Per-Ingvar Branemark, existe una alternativa a las técnicas de injerto óseo, utilizando el cuerpo del hueso cigomático como punto principal de anclaje a un implante osteointegrado intraoral. Este procedimiento permite al paciente recuperar la función orofacial en una sola etapa quirúrgica, con alta previsibilidad, menor morbilidad, tiempo y costos. En este artículo científico los autores presentan un conjunto de mejoras técnicas en el implante cigomático (S.I.N. - Implant System, São Paulo, Brasil) en combinación con un nuevo sistema de navegación dinámica llamado StealthStation™ (Medtronic, Dublin, Irland) utilizado por primera vez en este tipo de cirugía.

PALABRAS CLAVE: Implantes dentales. Cigoma. Maxilar.

INTRODUCTION

The rehabilitation of the orofacial function of totally and partially edentulous patients before the advent of the concept of osseointegration was carried out using removable prostheses. In 1965, osseointegrated implants were used for the first time to treat edentulous patients¹.

The osseointegration techniques for maxillary rehabilitation are more complex than those of mandibular rehabilitation, due to the proximity of the nasal cavities and maxillary sinuses, to the degree of maxillary bone resorption (particularly in the posterior region by early extractions, dental pathology and pneumatization of the maxillary sinus) and quality of the maxillary bone, more vascularized and less dense than the mandibular bone¹. Patients with adequate maxillary bone availability are the exceptions, most of them present different degrees of atrophy, which require alternative techniques for the use of existing bone (eg. pterygoid implants), autogenous or alloplastic bone grafts (eg. on-lay maxilla bone grafts, maxillary sinus bone grafts) or osteogenic distraction techniques (eg. Le Fort I maxillary fracture)². These procedures, in spite of being able to offer higher success rates for osseointegration, present disadvantages, namely the need for multiple surgical interventions, restriction of prosthesis use for a long transitional period (minimum 4 months), increased morbidity, higher surgical costs and hospitalization^{1,2}.

In the early 1990s, with his experience in animal and human research, P-I Branemark acknowledged that the introduction of implants in the maxillary sinuses did not necessarily compromise healthy breathing and considered the use of the zygomatic bone as an anchorage point for implants, which would ensure the prosthetic rehabilitation of mutilated patients, resulting from surgeries of tumor resection, trauma or congenital facial defects^{3,4}. As these interventions were successful and the long-term stability of these implants was verified, in 1997, Branemark developed the zygomatic implant, which provides bone fixation under conditions of severe resorption or bone loss in the posterior maxilla, with the advantage of eliminating the need for grafts bone in its intervention area^{1,4}.

CASE REPORT

In this scientific article, the authors present a set of technical improvements in the zygomatic implant (S.I.N. - Implant System, São Paulo, Brazil) in combination with a new dynamic navigation system called StealthStation™ (Medtronic, Dublin, Ireland) used for the first time in this type of surgery. Technical improvements were evaluated in terms of design, microbiological and biomechanical analysis.

Design

The new zygomatic implant (S.I.N. - Implant System, São Paulo, Brazil) is available in 13 different lengths, ranging from 32 to 62 mm. It is an implant with universal external hexagon connection, made of grade IV titanium, being surface treated by a double acid attack in the apical and cervical regions, sterilized by gamma radiation and coming with a mounter and cover-screw.

It has an angled head of 45°, which compensates for the angulation between the zygomatic bone and the maxilla and between two zygomatic implants, when placed in the same quadrant.

The apical diameter became Ø 3.85 mm with a length of 10 mm, this change aiming to enable the placement of implants in smaller zygomatic bones. Nkenke and colleagues⁵ studied the proportions of 30 zygomatic bones and found values of 19.99% ± 7.60% for trabecular bone and 83.18% ± 8.87% for cortical bone in the female group. The values for the male bones were 27.32% ± 9.49% for trabecular bone and 83.68% ± 6.35% for cortical bone. Those authors presented mean lateral-thickness measures of 7.60 ± 1.45 mm for female bones and 8.00 ± 2.26 mm for male bones. Despite less favorable values have been found in the female zygomatic bones, these differences were not statistically significant⁵.

The cervical diameter became Ø 4.5 mm with micro-screw threads in a length of 3 mm; this change aiming to increase the primary stability of the implant at the level of the alveolar ridge, most of the time very atrophic and without consistency. Keeping the bone around the implant head, a greater area of osteointegration is achieved and, as a consequence, peri-implant soft tissue coverage will be improved, increasing resistance to occlusal forces. Resorption of the thin palatal bone rapidly leads to oro-antral fistula followed by implant loss⁶.



Figure 1 - Technical improvements of the zygomatic implant in terms of design.

Microbiological Analysis

The implant body is now smooth, without screw threads and with a diameter of Ø 3.1 mm; this change aiming to reduce the intrasinus bacterial colonization around the implant body, increasing the adherence of the soft tissues that cover the implant and in clinical situations

of extra-sinus positioning, reducing the tactile perception by the patient.

Each type of sinus procedure presents a risk of complication, such as a damage to the alveolar antral artery resulting in hemorrhage, a perforation of the Schneider membrane or an obstruction of the antral meatal ostium complex. Current literature reports that the primary complication after zygomatic implants placement is chronic sinusitis, appearing with a frequency of 1.85% to 18.42% and resulting in atrophy of the maxillary sinus⁶.

Biomechanical Analysis

Static and dynamic loading tests for the newly developed zygomatic implants were performed in accordance with ISO 14801:2016 standards for static and dynamic loading tests for endosseous dental implants.

Briefly, for static loading tests, the measuring parameters were as follows: CENIC 016 testing machine for static evaluation of bending, test velocity of 5 mm/min, L distance of 11.0 mm, 5 specimens tested, ambient air at room temperature. Both maximum load (N) and maximum moment (N.m) were recorded for each specimen and mean \pm standard deviation was determined⁷⁻⁹.

With regard to dynamic loading tests, the measuring parameters were as follows: CENIC 017 testing machine for evaluation of bending fatigue, reference load of 706.3 N (6.36 N.m), test frequency of 15 Hz, minimum/maximum load R ratio of 0.1, tightening torque of 20 N.cm, L distance of 11 mm, number of run out cycles of 5×10^6 , polyacetal specimen holder, ambient air at room temperature. Maximum load (N), maximum moment (N.m) and the number of cycles for implant rupture were recorded to evaluate the zygomatic implant tolerance limit⁷⁻⁹.

Dynamic Navigation

3D implant planning and mapping that plan to the real surgical environment are two important steps in implant rehabilitation¹⁰⁻¹¹. Misplaced implants can create difficult aesthetics, functional and biological problems and may result in implant loss¹²⁻¹⁴.

There are three ways to transfer a planned implant's position into the real patient's jawbone: a) mental navigation, so-called freehand navigation; b) static navigation using surgical templates¹⁵ and c) dynamic navigation¹⁶⁻¹⁷.

The freehand approach is totally dependent on the surgeon's experience, skills and mindset during treatment and creates the highest deviations compared to the other approaches¹¹.

The usage of surgical templates provides a higher accuracy compared to freehand surgery, but has a few limitations, such as the inability to modify the plan once the surgical template has been manufactured. Surgical templates require longer drills which can make their use

difficult in patients with mouth open limitations. Other concerns are irrigation issues and incompatibility with advanced surgical protocols.

Dynamic navigation is, at present, the most effective way to transfer the planned implant's position to the real patient as it guides the surgeon's motions using real-time feedback. It is especially useful to reduce flapped procedures with the advantage of improved soft-tissue healing, patient comfort and reduce bone resorption. Dynamic navigation allows planning modifications at any time, even during treatment, and can be used in cases with limited mouth opening or in combination with osseodensification drills.

StealthStation™

The StealthStation™ surgical navigation system enables to precisely track the location of surgical instruments throughout a procedure. The system introduces a combination of hardware, software, tracking algorithms, image data merging, and specialized instruments to help guide surgeon during surgical procedures¹⁸⁻¹⁹.

The StealthStation™ System is intended as an aid for precisely locating anatomical structures in either open or percutaneous procedures. The system is indicated for any medical condition in which the use of stereotactic surgery may be appropriate, and where reference to a rigid anatomical structure, such as the skull, a long bone, or vertebra, can be identified relative to a tomography or magnetic resonance, based model, fluoroscopy images, or digitized landmarks of the anatomy¹⁸⁻¹⁹.

The surgical navigation system offers both optical and electromagnetic tracking capabilities, integration with external devices like microscopes and ultrasound, a broad array of instrument offerings, and core software applications for neurosurgery, spine procedures and maxillofacial surgery¹⁸⁻¹⁹.

During navigation, the system identifies the location of the tip and the trajectory of the tracked instrument in images and models that the user has selected for viewing. The surgeon may also create and store one or more surgical plane trajectories prior to surgery and simulate the progression along these trajectories. In surgery, the software can show the actual position at the tip of the instrument and its trajectory relating them to the pre-surgical plane¹⁸⁻¹⁹.

The system consists of a platform, clinical software, surgical instruments and a reference system (including patient and instrument trackers). Patient images can be displayed by software from various perspectives (axial, sagittal, coronal, oblique) and three-dimensional (3D)¹⁸⁻¹⁹.

The use of this navigation system has not yet been used in surgery for zygomatic implants, so some challenges arose namely: choosing the appropriate instruments, assembling the equipment and learning curve.

The main objective of this innovation was the placement of the zygomatic implant with the possibility of verifying the direction and length of the osteotomy intra-operatively and in real time, checking the proximity to the relevant anatomical structures and maximizing the bone availability of the zygomatic bone for anchoring the implant.

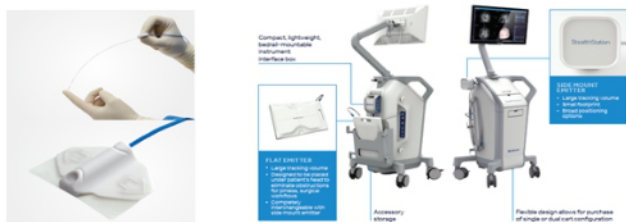

Figure 2 - StealthStation™ System equipment apparatus.

A 56-year-old male patient, caucasian, attended the oral-maxillofacial surgery consultation at Clitrofa - Centro Médico, Dentário e Cirúrgico, in Trofa - Portugal, to perform an implant-supported rehabilitation of the upper jaw. The clinical evaluation reveals a partially edentulous jaw with the presence of teeth 1.1, 1.2, 1.3, 2.1 and 2.4 which supported a removable prosthesis (Figure 3).

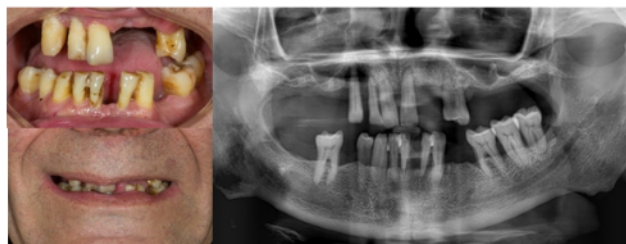

Figure 3 - Pre-surgical evaluation. Appearance of the contour of the lips and orbicularis of the mouth. Dental occlusion and orthopantomography.

To complete the pre-surgical evaluation, high-definition computed tomography was performed, which revealed an extremely resorbed maxilla in the posterior sector. Clinical case with indication for placing 2 zygomatic implants in the posterior sector and 4 standard implants in the anterior sector of the maxilla (Figure 4).

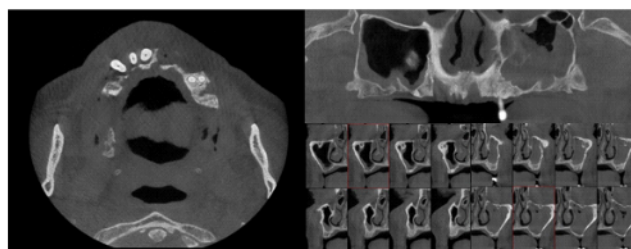


Figure 4 - Initial computed tomography with sagittal, coronal and cross sections.

Computed tomography was introduced in StealthStation™ and the match between the patient's real anatomy and imaging was performed. The flat emitter was placed below the patient's head to eliminate obstructions for pinless, and surgical workflows (Figure 5).

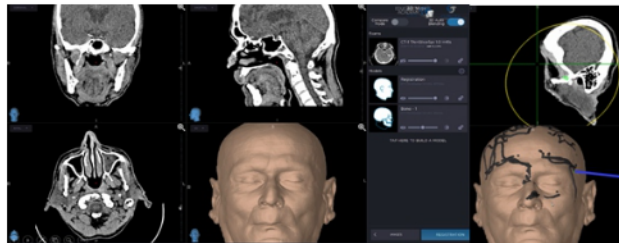


Figure 5 - StealthStation™ matches the computer tomography imaging with patient's real anatomy.

After full-thickness flap with bilateral identification of the infraorbital nerves, an osteotomy was performed to create a bone window to access the interior of the maxillary sinus. The navigation instrument most suitable for this type of surgery was chosen for its flexibility, thickness and length. The images displayed on the monitor are in real time intraoperatively allowing the alteration and verification of the osteotomy in the space planes. Confirmation of existing bone availability, maintenance of the integrity of the relevant anatomical structures and placement of the zygomatic implant in the ideal position for each clinical case are ensured. Zygomatic implants are placed according to this check list (Figures 6 and 7).

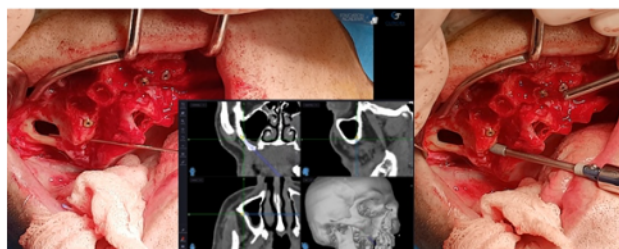


Figure 6 - Placement of the 1st quadrant zygomatic implant with the help of the navigation instrument.

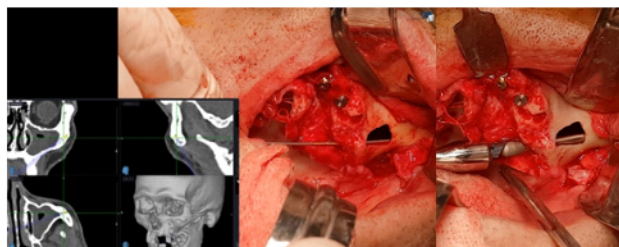


Figure 7 - Placement of the 2nd quadrant zygomatic implant with the help of the navigation instrument.

The three-dimensional positioning of the zygomatic implants allowed to achieve an excellent primary stability

as well as an adequate positioning for prosthetic rehabilitation (Figure 8).

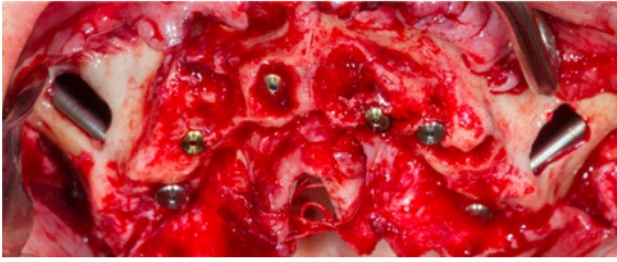

Figure 8 - Intraoperative aspect of implant placement.

The images provided intraoperatively and in real time are of great definition and highly informative. The system also allows the introduction of a color code to establish safety limits with respect to the length and diameter of the zygomatic implants. Navigation can also be used in other standard implants (Figure 9).

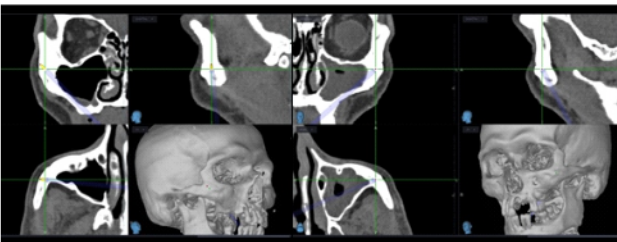


Figure 9 - Three-dimensional intraoperative images provided by the navigation system.

After completion of the surgery, a new high definition computed tomography was performed to check the final position of the 2 zygomatic implants placed in the posterior sector of the maxilla and the 4 standard implants placed in the anterior sector of the maxilla (Figure 10).

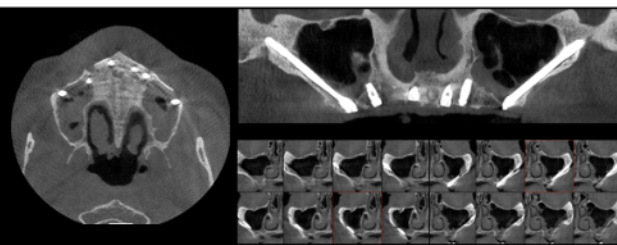


Figure 10 - Final computed tomography with sagittal, coronal and cross sections.

In static loading tests, the newly developed zygomatic implants have shown an average maximum load of 847.29 ± 38.81 N and an average maximum moment of 7.63 ± 0.35 N.m. Figure 11 shows the force vs displacement graph obtained for the analyzed samples.

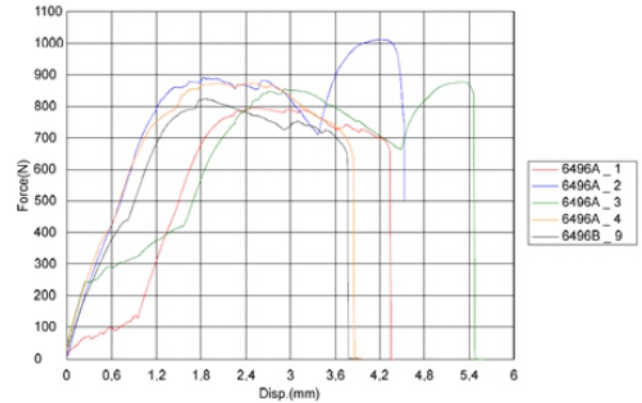


Figure 11 - Force (N) versus displacement (mm) curves obtained for the static loading test of zygomatic implants.

In dynamic loading tests, the newly developed zygomatic implants have resisted a maximum load of 470.88 N (66.6% of reference load) and a maximum moment of 4.24 N.m during 5×10^6 mechanic loading cycles. Higher test loads and moments have resulted in fracture/rupture of the newly zygomatic implants, as can be shown in Figure 12.

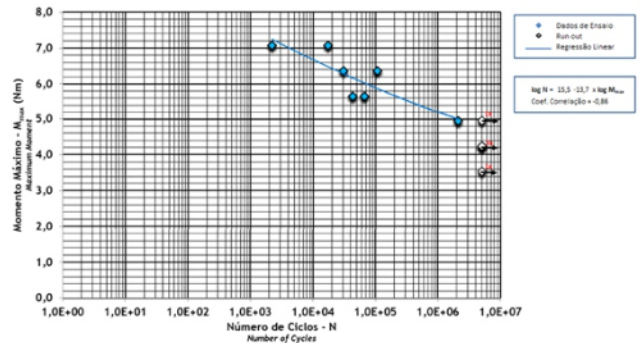


Figure 12 - Maximum moment (N.m) versus number of cycles graph obtained for the dynamic loading test of zygomatic implants.

In postoperative, high definition computed tomography was used to verify a correspondence between the final position of the zygomatic implants and the images observed in the intraoperative StealthStation™.

CONCLUSION

In zygomatic surgery, planning, knowledge and prevention of complications, either of surgical or prosthetic nature, are essential. The newly developed zygomatic implants have shown promising biomechanical properties in static and dynamic loading tests. They present a relatively high resistance to mechanical load (maximum load of 847.29 ± 38.81 N) and a good resistance to fatigue, supporting 470.88 N of force (66.6% of reference load)

after 5×10^6 mechanic loading cycles.

Future studies comprising a comparison with other commercially available zygomatic implants should give a more complete insight on the biomechanical potential of these zygomatic implants. In addition, in vivo performance evaluation of these systems must be attempted in order to confirm these promising preliminary data.

The StealthStation™ navigation system is an intraoperative surplus in the placement of the zygomatic implant and will have an immediate inclusion in the surgical protocols. However, there are some aspects that should be improved, namely the incorporation of a virtual library with the dimensions of the available zygomatic implants and the adaptation of the navigation system to the contra-angle used in this type of surgery.

REFERENCES

- Rigolizzo M, Camilli J, Francischone C, Padovani C, Bra?nemark P-I. Zygomatic bone: anatomic bases for osseointegrated implant anchorage. *Int J Oral Maxillofac Implants*. 2005;20(3):441-7.
- Ferrara E, Stella J. Restoration of the edentulous maxilla: The case for the zygomatic implants. *J Oral Maxillofac Surg*. 2004;62:1418-12.
- Malevez C, Daelemans P, Adriaessens P, Durdu F. Use of zygomatic implants to deal with resorbed posterior maxillae. *Periodontology*. 2003;33:82-9.
- Duarte F, Ramos C. All-On-Ten - função imediata com implantes Bra?nemark® em pacientes desdentados totais. *Aesthet Implant*. 2006;Primavera:34-9.
- Nkenke E. Anatomic site evaluation of the zygomatic bone for dental implant placement. *Clin Oral Implants Res*. 2003;14:72-9.
- Al-Nawas B, Wegener J, Bender C, Wagner W. Critical soft tissue parameters of the zygomatic implant. *J Clin Periodontol*. 2004;31:497-500.
- Gümrükçü Z. Biomechanical evaluation of zygomatic implant use in patients with different buccal maxillary defect levels. *Int J Oral Maxillofac Implants*. 2019;34(6):e115-22.
- Ishak M.I., Abdul Kadir M. Biomechanical considerations. In: *Biomechanics in dentistry: evaluation of different surgical approaches to treat atrophic maxilla patients*. Berlin: Springer; 2013.
- Rossetti PH, Bonachela WC, Rossetti LM. Relevant anatomic and biomechanical studies for implant possibilities on the atrophic maxilla: critical appraisal and literature review. *J Prosthodont*. 2010;19(6):449-57.
- Somogyi-Ganss E, Holmes HI, Jokstad A. Accuracy of a novel prototype dynamic computer-assisted surgery system. *Clin Oral Implants Res*. 2015;26(8):882-90.
- Block MS, Emery RW, Lank K, Ryan J. Implant placement accuracy using dynamic navigation. *Int J Oral Maxillofac Implants Surg*. 2017;75(7):1377-86.
- Umamathiy T, Jayam C, Anila BS. Overview of surgical guides for implant therapy. *J Dent Implants*. 2015;5(1):48-52.
- Kate MA, Plaskar S, Kappor P. Implant failure: a dentist's nightmare. *J Dent Implants*. 2016;6(2):51-6.
- Palma-Carrió C, Maestre-Ferrin I, Peñarrocha-Oltra D, Peñarrocha-Dago MA, Peñarrocha-Diago M. Risk factors associated with early failure of dental implants. A literature review. *Med Oral Patol Oral Cir Bucal*. 2011;16(4):514-7.
- Borisov R. Radiological templates and CAD/CAM surgical guides. A literature review. *JIMAB*. 2016;22(3):1285-95.
- D'ahese J, Ackhurst J, Bruyn H. Immediate loading with dynamic navigation implant surgery. *Int Mag Oral Implantol*. 2015;3:34-7.
- D'haese J, Van De Velde T, Komiyama A, Hultin M, De Bruyn H. Accuracy and complications using computer-designed stereolithographic surgical guides for oral rehabilitation by means of dental implants: a review of the literature. *Clin Implant Dent Relat Res*. 2012;14(3):321-35.
- Gralla J, Nimsky C, Buchfelder M, Fahlbusch R, Ganslandt O. Frameless stereotactic brain biopsy procedures using the Stealth Station: indications, accuracy and results. *Zentralbl Neurochir*. 2003;64(4):166-70.
- Ganslandt O, Behari S, Gralla J, Fahlbusch R, Nimsky C. Neuronavigation: concept, techniques and applications. *Neuro India*. 2002;50(3):244-55.