







# Surgical approach combining implantoplasty and reconstructive therapy with locally delivered antibiotic in the treatment of peri-implantitis: A prospective clinical case series

Iria González Regueiro DDS, MSc, PhD<sup>1</sup> | Natalia Martínez Rodríguez DDS, MSc, PhD<sup>1</sup>  |  
 Cristina Barona Dorado DDS, MSc, PhD<sup>2</sup>  | Ignacio Sanz-Sánchez DDS, MSc, PhD<sup>3</sup>  |  
 Eduardo Montero DDS, MSc, PhD<sup>3</sup>  | Javier Ata-Ali DDS, MS, MPH, PhD<sup>4,5,6</sup>  |  
 Fernando Duarte DDS, MSc<sup>7</sup> | José María Martínez-González DDS, MD, PhD, MDV, FEBOS<sup>2</sup> 

<sup>1</sup>Hospital Virgen de La Paloma, Madrid, Spain

<sup>2</sup>School of Dentistry, Complutense University of Madrid, Spain

<sup>3</sup>Etiology and Therapy of Periodontal and Peri-Implant Diseases (ETEP) Research Group, University Complutense, Madrid, Spain

<sup>4</sup>Faculty of Health Sciences, Department of Dentistry, Universidad Europea de Valencia, Valencia, Spain

<sup>5</sup>Public Dental Health Service, Conselleria de Sanitat Universal i Salut Pública, Generalitat Valenciana, Valencia, Spain

<sup>6</sup>Department of Surgery and Medical-Surgical Specialities, Area of Orthodontics, University Medical and Dental School, University of Oviedo (Spain), Instituto Asturiano de Odontología, Oviedo, Spain

<sup>7</sup>Instituto Clitrofa, Trofa, Portugal

## Correspondence

Javier Ata-Ali, Public Dental Health Service, Hospital Universitario y Politécnico la Fe, Avenida Fernando Abril Martorell, 106, 46026 Valencia, Spain.  
 Email: javiataali@hotmail.com

## Abstract

**Background:** Nonsurgical treatment, resective surgery, reconstructive surgery, or combined approaches have been proposed for the treatment of peri-implantitis, with variable results.

**Purpose:** To evaluate the 1-year clinical and radiographic outcomes following combined resective and reconstructive surgical treatment with topical piperacillin/tazobactam antibiotic in the management of peri-implantitis.

**Material and Methods:** Forty-three patients diagnosed with peri-implantitis were included. Surgical treatment consisted of implantoplasty of the supra-crestal component of the defect, the application of a topical antibiotic solution over the implant surface, and subsequent reconstruction of the intra-osseous component of the peri-implant defect. The primary outcome was disease resolution, defined as the absence of bleeding on probing (BoP) and/or suppuration on probing (SoP), a peri-implant pocket probing depth (PPD)  $\leq 5$  mm, and no bone loss  $>0.5$  mm 1 year after surgery. Secondary outcomes included changes in BoP, PPD, SoP, and peri-implant marginal bone levels. One implant per patient was included in the analysis.

**Results:** The treatment success rate of the 43 dental implants included in the study was 86% at 1 year after surgery. Mean PPD and BoP decreased from  $6.41 \pm 2.11$  mm and 100% at baseline to  $3.19 \pm 0.99$  mm ( $p < 0.001$ ) and 14% ( $p < 0.001$ ) at 1 year, respectively. SoP was significantly reduced from 48.8% at baseline to 0% 1 year after surgery ( $p < 0.001$ ). Radiographically, a mean defect fill of  $2.64 \pm 1.59$  mm was recorded ( $p < 0.001$ ).

**Conclusions:** The combination of a resective and reconstructive surgical approach together with locally delivered antibiotic achieved a high disease resolution rate after 1 year of follow-up and constitutes a viable option for the management of peri-implantitis.

This is an open access article under the terms of the Creative Commons Attribution-NonCommercial-NoDerivs License, which permits use and distribution in any medium, provided the original work is properly cited, the use is non-commercial and no modifications or adaptations are made.

© 2021 The Authors. *Clinical Implant Dentistry and Related Research* Published by Wiley Periodicals LLC

**KEYWORDS**

bone loss, case report, implantoplasty, local anti-infective agent, peri-implantitis, regenerative surgery

**Summary Box****What is known**

The combined surgical treatment of peri-implantitis may offer good clinical and radiographic outcomes. However, the complex defect configuration found in many cases of peri-implantitis may jeopardize mechanical surface decontamination. For this reason, the adjunctive use of local antibiotics could improve treatment response.

**What this study adds**

This is the first study to assess the local application of piperacillin/tazobactam antibiotic as an adjunct to combined surgical therapy of peri-implantitis. This antibiotic has shown promising results when treating other infections in the mouth, with minimal bacterial resistances.

## 1 | INTRODUCTION

The most common biological complications associated with dental implants are inflammatory conditions of the surrounding soft and hard tissues secondary to the accumulation of bacterial biofilm. Such conditions are referred to as peri-implant disease, which in turn can be divided into peri-implant mucositis and peri-implantitis.<sup>1</sup> Peri-implantitis is a plaque-associated pathological condition characterized by the presence of an inflammatory infiltrate in the connective tissue of the mucosa that progresses apically and induces progressive loss of supporting bone.<sup>2</sup>

Globally, it is difficult to estimate the real magnitude of peri-implant diseases, due to the great variability in the reported prevalences. In effect, the reported prevalence of peri-implantitis ranges from 1% to 47% at patient level.<sup>3</sup> This wide range can be explained by the different definitions used and great heterogeneity regarding follow-up and the studied populations.<sup>4</sup> For this reason, it has been recommended that a threshold of  $\geq 3$  mm of bone loss, together with clinical signs of inflammation, should be used in epidemiological studies to define peri-implantitis.<sup>2</sup> Considering this recommendation, a recent study carried out in Spain in 275 patients found a prevalence of peri-implantitis of 14% at patient level.<sup>5</sup>

For many years, no specific criteria were established to assess treatment success or to define specific therapeutic protocols in the treatment of peri-implantitis.<sup>6</sup> Treatment success should be based on a composite outcome defined as disease resolution, consisting of a peri-implant pocket probing depth (PPD)  $\leq 5$  mm, the absence of bleeding on probing and suppuration on probing (BoP/SoP), and no further bone loss  $>0.5$  mm.<sup>7,8</sup>

Different protocols have been proposed for the treatment of peri-implantitis, including nonsurgical and surgical approaches. However, the most recent evidence based on *in vitro*, animal and clinical studies, has found no superiority of any specific decontamination method or treatment modality.<sup>9,10</sup> Nevertheless, some treatment approaches seem to

be able to stop or delay the peri-implant destruction process. For example, a 10-year follow-up study of patients undergoing resective therapy together with a strict supportive program revealed that 84% of the implants that achieved disease resolution after surgery remained without signs of peri-implant disease over the study period.<sup>11</sup>

The decision-making process in the treatment of peri-implantitis may be based on the configuration of the peri-implant bone defect. In this regard, a classification has been published, confirming that most of the defects exhibit a supra- and intra-bony component with or without buccal dehiscence.<sup>12</sup> In these cases, a combined approach has been proposed, consisting of implantoplasty of the supra-osseous component of the defect (also in the presence of dehiscence) and reconstruction of the intra-bony component using guided bone regeneration (GBR).<sup>12-14</sup>

In order to improve the final outcome, the use of antibiotics has also been evaluated as an adjunct to reconstructive surgery.<sup>15-17</sup> Antibiotic resistances constitute a major challenge for health professionals worldwide, with the potential to create important problems for health care.<sup>18</sup> However, the local application of antibiotics as an adjunct to mechanical decontamination methods has been proposed in the treatment of peri-implantitis, seeking to avoid the undesirable effects of systemic antibiotics. In this respect, the present prospective study was carried out to assess the effectiveness of a new surgical protocol combining implantoplasty and reconstructive therapy together with an antibiotic solution of piperacillin/tazobactam in patients diagnosed with peri-implantitis.

## 2 | MATERIAL AND METHODS

### 2.1 | Study design and participants

A prospective case series study was conducted following the ethical principles of the Declaration of Helsinki. Written informed consent was obtained from all eligible patients prior to enrolment, and ethical

approval was obtained from the Institutional Review Board of San Carlos Clinical Hospital (Madrid, Spain) (Ref.: 18/006-E). The study was conducted in compliance with the CARE guidelines.

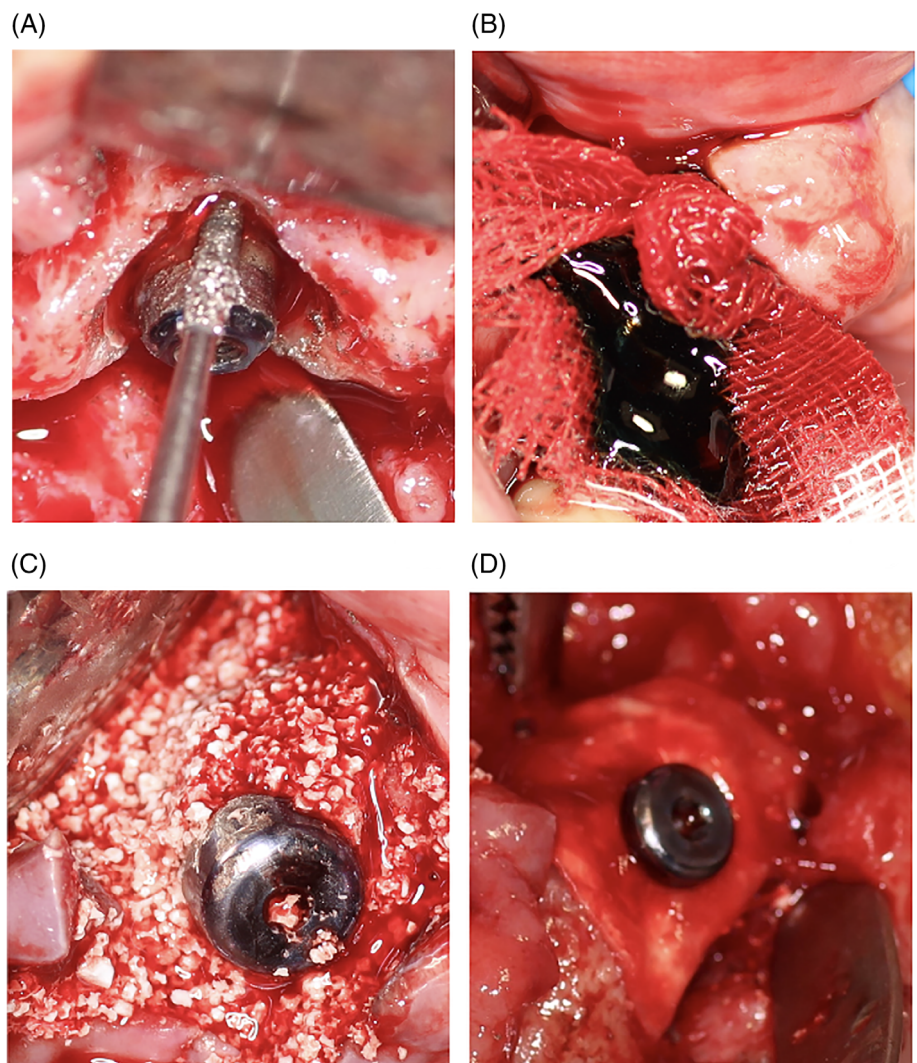
Participants were consecutively screened for inclusion from among those visiting the Department of Dental Clinical Specialties (Faculty of Dentistry, Complutense University, Madrid, Spain) or Virgen de La Paloma Hospital (Madrid, Spain). The following inclusion criteria were considered: (i) patients  $\geq 18$  years of age; (ii) at least one dental implant diagnosed with peri-implantitis (PPD  $> 5$  mm, BoP and/or SoP, and radiographic bone loss  $\geq 3$  mm)<sup>2</sup>; (iii) American Society of Anesthesiologists score I or II; and (iv) presence of a type 1b (infra-osseous defect together with dehiscence), type 3b (2–3 walls defect plus horizontal bone loss), or type 3c defect (circumferential defect plus horizontal bone loss), based on the classification proposed by Monje and colleagues.<sup>19</sup>

Patients were excluded if one or more of the following criteria was present: (i) untreated periodontitis; (ii) pregnant or breastfeeding women; (iii) immunosuppression and/or treatment with corticosteroids within the last 12 months; (iv) treatment with anticoagulants or acetylsalicylic acid; (v) treatment with bisphosphonates; (vi) signs of

dysplasia or precancerous lesions; (vii) allergy to betalactam antibiotics; (viii) previous surgical treatment of peri-implantitis on the included implant(s); and (ix) presence of implant mobility. If during surgery, and after raising the flap and removing the granulation tissue, the defect morphology failed to match the inclusion criteria, the patient was excluded from the study.

## 2.2 | Intervention

All surgeries were performed by the same surgeon with more than 35 years of experience (JMMG). All patients underwent supra- and subgingival debridement using steel curettes (Hu-Friedy, Chicago, IL, USA) and an ultrasonic scaler (Cavitron, Dentsply, NY, USA), and received oral hygiene instructions 1 month before surgery. The prosthesis was removed, and a healing abutment was screwed into place. Patients were required to present full mouth plaque and full mouth bleeding scores of  $\leq 20\%$  before surgery. One week before surgery, subgingival irrigation with a solution of piperacillin/tazobactam 100/12.5 was applied inside the peri-implant pocket.



**FIGURE 1** Different phases of the combined surgical therapy of a peri-implantitis defect. (A) Implantoplasty of the buccal dehiscence. (B) Dressing impregnated with 37% orthophosphoric acid and 2% chlorhexidine digluconate. (C) Synthetic hydroxyapatite bone substitute hydrated with piperacillin/tazobactam 100/12.5 mg and compacted into the defect. (D) Resorbable collagen membrane hydrated with piperacillin/tazobactam solution placed over the graft

At the time of surgery, full-thickness flaps were raised using intrasulcular and vertical releasing incisions to expose the buccal and lingual portion of the implant. Granulation tissue was removed with Teflon curettes, and the implant surface was debrided with an ultrasonic scaler (Cavitron, Dentsply, NY, USA). Implantoplasty was performed at the supra-osseous component of the defect and at the buccal and/or lingual dehiscences using large, medium, and fine diamond drills (Italmed, Firenze, Italy) (Figure 1A). The chemical decontamination of the exposed implant surface was performed with a kit containing orthophosphoric acid, chlorhexidine, and the antibiotic solution (Implacure® [MedTech Dental AG, Switzerland]). Briefly, the walls of the defect were protected with sterile gauzes, and the implant surface was decontaminated with 37% orthophosphoric acid and 2% chlorhexidine using a dual syringe containing both products. After 2 min, the implant surface was washed out with sterile saline solution, and the implant surface was scrubbed with gauze impregnated with piperacillin/tazobactam for 1 min (Figure 1B).

Following decontamination of the implant surface, GBR was performed using a synthetic hydroxyapatite bone substitute with a particle size of 250–1000  $\mu\text{m}$  (Osbone®, Curasan, Kleinostheim, Germany) that was hydrated with piperacillin/tazobactam 100/12.5 mg and compacted into the defect (Figure 1C). A resorbable collagen membrane (Osgide®, Curasan, Kleinostheim, Germany) likewise hydrated with the piperacillin/tazobactam solution was placed over the graft and fixed with titanium tacks (Curasan, Kleinostheim, Germany) (Figure 1D). Flaps were sutured with synthetic 4/0 suture (Supramid®, Laboratorio Aragón, Barcelona, Spain) with the aim of securing closure by primary intention.

Anti-inflammatory (dexketoprofen trometamol 25 mg, Enantyum®, Menarini, Badalona, Spain) and analgesic medication (magnesium metamizol 575 mg, Nolotil®, Boehringer Ingelheim, Barcelona, Spain) was used every 8 h as needed. No systemic antibiotics were prescribed. Two weeks after surgery, the sutures were removed, and the prosthesis was placed back.

## 2.3 | Study visits and outcomes

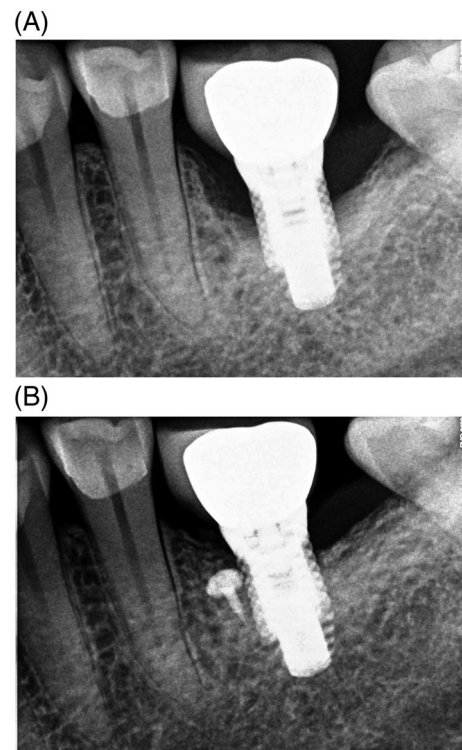
### 2.3.1 | Follow-up visits

At the screening visit, a full-mouth periodontal evaluation was carried out and periapical radiographs of all implants were taken. All the clinical and radiographic outcomes were registered at baseline and 1 year after surgery (Figure 2). Patients were scheduled 15 days after surgery and then at 1, 3, 6, and 12 months. At 3, 6, and 12 months of follow-up, the patients underwent supragingival plaque removal using Teflon curettes.

### 2.3.2 | Clinical parameters

The following clinical parameters were evaluated:

- Pocket probing depth (mm) at four sites per implant using a manual periodontal probe (CP-12, Hu-Friedy, Chicago, IL, USA).



**FIGURE 2** Periapical radiograph at baseline (A) and 1 year after surgery (B) showing a complete radiographic defect fill

- Bleeding on probing at four sites per implant based on a dichotomous (0/1) scale using a manual periodontal probe.<sup>20</sup>
- Suppuration on probing at four sites per implant based on a dichotomous (0/1) scale using a manual periodontal probe.
- Disease resolution defined as a composite outcome that included the absence of BoP and/or SoP, PPD  $\leq 5$  mm, and no bone loss  $>0.5$  mm 1 year after surgery.<sup>7</sup>
- Type of peri-implantitis defects according to their morphology: Class I (infra-osseous/vertical defect), Class II (supracrestal/horizontal defect), or Class III (combined defect).<sup>19</sup>

One examiner in each center recorded all the clinical outcomes. The calibration session consisted of repeated examinations of 10 implants in 10 patients, spaced 1 week apart before initiation of the study. The intra- and inter-examiner reproducibility achieved  $\pm 0.5$  mm for PPD in 89% and 85% of the cases, respectively.

### 2.3.3 | Radiographic assessment

Standardized periapical radiographs (Kodak 5100 radiovisiographic system, Kodak Dental System, Atlanta, GA, USA) using the parallel technique (Rinn® system, Dentsply, Weybridge, UK) were used to evaluate the changes in radiographic peri-implant marginal bone level (MBL). Furthermore, PPD was used to represent the peri-implantitis defects according to their morphology combined with periapical radiography.<sup>16</sup> Scanned images were measured both at the mesial and distal sites of the selected implant using as landmarks the implant

shoulder and the first bone-implant contact. The implant length was used to scale measurements by means of image analysis software (Image-J, National Institutes of Health, MD, USA). An experienced investigator (CBD) performed all the radiographic measurements, with an intra-examiner agreement (correlation coefficient) of 0.985, as determined by means of a calibrating session in which 20 random radiographs were measured twice by the same examiner.

## 2.4 | Statistical analysis

The primary outcome variable was disease resolution (treatment success). Secondary outcomes included mean changes in PPD, BoP, SoP,

and MBL. One dental implant per patient was included in the analysis, so each variable was analyzed at patient level. If a patient presented more than one implant meeting the inclusion criteria, all the implants were treated with the studied protocol, but only one was randomly selected for the analysis.

Data were expressed as means, standard deviations, medians, and ranges. The Kolmogorov–Smirnov test and Shapiro–Wilk test were used to assess normal data distribution. Inferential statistical processing was carried out with the 95% confidence interval (95% CI). A logistic regression analysis was performed to determine the factors associated with disease resolution, using as dependent variable the composite outcome for treatment success proposed by Carcuac and colleagues<sup>7</sup> (ie, absence of BoP and/or SoP, PPD ≤5 mm and bone

**TABLE 1** Mean values (SDs) or percentages (n, %) for demographic, clinical, and radiographic parameters

Variable	All patients/implants (n = 43)	Disease resolution		p value*
		Yes (n = 37)	No (n = 6)	
Age (years)	60.2 (9.3)	60.7 (9.5)	57.0 (7.8)	0.370
Gender				
Male	15 (34.9%)	13 (35.1%)	2 (33.3%)	0.932
Female	28 (65.1%)	24 (64.9%)	4 (66.7%)	
Smoking				
Never or former smokers	21 (48.8%)	19 (51.4%)	2 (33.3%)	0.413
Smokers	22 (51.2%)	18 (48.7%)	4 (66.7%)	
Position				
Anterior (I/C)	16 (37.2%)	13 (35.1%)	3 (50.0%)	0.783
Premolar	9 (20.9%)	8 (21.6%)	1 (16.7%)	
Molar	18 (41.9%)	16 (43.2%)	1 (33.3%)	
Arch				
Maxilla	16 (37.2%)	13 (35.1%)	3 (50.0%)	0.485
Mandible	27 (62.8%)	24 (64.9%)	3 (50.0%)	
Time in function (years)	7.8 (3.7)	8.4 (3.6)	4.0 (1.7)	0.006
Oral hygiene				
Brushing 1–2 times/day	10 (23.2%)	7 (18.9%)	3 (50.0%)	0.208
Brushing 3 times/day	6 (14.0%)	5 (13.5%)	1 (16.7%)	
Brushing 3 times/day + interdental hygiene	27 (62.8%)	25 (67.6%)	2 (33.3%)	
Defect configuration				
Class I defects	31 (72.1%)	29 (78.4%)	2 (33.3%)	0.153
Class III defects	12 (27.9%)	8 (21.6%)	4 (66.7%)	
PD (mm) at baseline	6.4 (2.1)	6.6 (2.1)	5.2 (1.7)	0.135
BoP at baseline	43 (100%)	37 (100%)	6 (100%)	-
SoP at baseline	21 (48.8%)	19 (51.3%)	2 (33.3%)	0.413
MBL (mm) at baseline	5.8 (2.1)	6.0 (2.1)	4.9 (1.4)	0.256
PD (mm) at 12 months	3.2 (1.0)**	3.1 (0.9)**	3.9 (1.3)	0.067
BoP at 12 months	6 (14.0%)**	0 (0%)**	6 (100%)	<0.001
SoP at 12 months	0 (0%)**	0 (0%)**	0 (0%)**	-
MBL (mm) at 12 months	3.2 (2.2)**	3.1 (2.2)**	3.3 (2.3)	0.903

Abbreviations: BoP, bleeding on probing; I/C, incisors and canines; MBL, marginal bone loss; n, number of patients/implants; PD, probing depth; SD, standard deviation; SoP, suppuration on probing.

\*p value for the comparison between successfully treated implants and not resolved peri-implantitis.

\*\*Statistically significant difference when compared to baseline ( $p < 0.001$ ).

loss  $\leq 0.5$  mm 1 year after surgery), and as independent variables patient age, gender, smoking (smokers vs never smokers), position (anterior/premolar/molar), arch (maxilla or mandible), time in function, oral hygiene, defect configuration (Class I vs Class III defects), mean PPD at baseline, deepest PPD at baseline, presence/absence of supuration, and MBL at baseline. The results of the logistic regression analyses were reported as odds ratios (ORs) in univariate associations and in a multivariate model in which a “change-in-estimate” approach (a change in adjusted OR for a covariate of  $\geq 10\%$  compared to the crude OR) was used. Results were considered statistically significant at  $p < 0.05$ . Software packages (SPSS<sup>®</sup> version 23.0, IBM, Armonk, NY, USA; and STATA13.1, StataCorp, College Station, TX, USA) were used for all data analyses.

### 3 | RESULTS

#### 3.1 | Study sample

Seventy-three consecutive patients were screened, of whom 43 fulfilled the inclusion criteria and were recruited in the study (12 from Virgen de La Paloma Hospital and 31 from the Complutense University, Madrid). The baseline demographic, clinical, and radiographical parameters are depicted in Table 1. All patients presented bone level implants, 38 with an 0.3-mm machined collar at the level of the implant shoulder (BioHorizons RBT; Internal Implants, Birmingham,

**TABLE 2** Number of patients/implants (%) with various probing depth (PD) and marginal bone level (MBL) categories at baseline and 12 months after treatment

	Baseline	12 months
Mean PD		
PD < 4 mm	3 (7.0%)	30 (69.8%)
4 mm $\leq$ PD $\leq$ 5 mm	7 (16.2%)	11 (25.6%)
5 mm $\leq$ PD $\leq$ 6 mm	6 (14.0%)	1 (2.3%)
PD $\geq$ 6 mm	27 (62.8%)	1 (2.3%)
Mean MBL		
MBL $\leq$ 3 mm	2 (4.6%)	25 (58.1%)
3 mm < MBL $\leq$ 5 mm	12 (27.9%)	11 (25.6%)
5 mm < MBL $\leq$ 7 mm	22 (51.2%)	6 (14.0%)
MBL > 7 mm	7 (16.3%)	1 (2.3%)

MBL change	All cases	Disease resolution	Unsuccessful cases
< -0.5 mm	0 (0%)	0 (0%)	0 (0%)
-0.5 to 0.5 mm	4 (9.3%)	2 (5.4%)	2 (33.3%)
0.5 to 2 mm	8 (18.6%)	6 (16.2%)	2 (33.3%)
2 to 3 mm	7 (16.3%)	7 (18.9%)	0 (0%)
>3 mm	24 (55.8%)	22 (59.5%)	2 (33.3%)

Note: Negative values (–) indicate radiographic bone loss. Positive values indicate radiographic defect fill.

AL, USA) and 5 with an acid-etched surface up to the implant-abutment interface (Phibo TSA™, Phibo Dental Solutions).

All patients completed the 1-year follow-up period. There were no intra- or postoperative complications, no implants were lost, and no implant fractures were reported.

#### 3.2 | Clinical and radiographic outcomes

All patients presented screw-retained restorations (30 with single-crown restorations, 5 with two implant-abutment prosthesis, and 1 with three implant-abutment prosthesis). At 12 months, 86% ( $n = 37$ ) of the peri-implantitis lesions showed disease resolution. Among the unresolved cases, all presented BoP, one out of 6 implants (2.3% of the total sample) had mean PPD > 5 mm at 12 months, and none presented further bone loss >0.5 mm. Moreover, four cases out of six with unsuccessful results presented a radiographic defect fill >0.5 mm. The differences in the clinical outcomes between successful and unsuccessful implants are shown in Table 1.

Bleeding on probing was present in 100% of the patients at baseline. However, 1 year after surgery, BoP showed a reduction of 86% at patient level ( $p < 0.001$ ). SoP was present in 48.8% of the patients at baseline and was completely eradicated 1 year after surgery ( $p < 0.001$ ). At 12 months, the mean PPD was seen to have decreased from  $6.4 \pm 2.1$  mm to  $3.2 \pm 1.0$  mm, representing a mean reduction of  $3.2 \pm 2.0$  mm ( $p < 0.001$ ). The frequency distribution of PPD at baseline and 12 months after treatment is depicted in Table 2.

At baseline, the mean MBL was  $5.8 \pm 2.1$  mm. One year after surgery the mean value was  $3.2 \pm 2.2$  mm, representing a mean radiographic defect fill of  $2.6 \pm 1.5$  mm ( $p < 0.001$ ). The frequency distribution of MBL at baseline and 12 months after treatment is depicted in Table 2. The percentage of subjects with mean MBL > 5 mm at baseline was 67.5% (29 subjects), while the percentage at 12 months decreased to 16.3% (7 subjects). The frequency distribution of the bone level changes is shown in Table 3. Twelve months after treatment, 55.8% of the implants presented a radiographic defect fill >3 mm.

#### 3.3 | Factors associated with disease resolution

The results of the univariate regression analysis indicated that the odds of achieving a successful outcome were greater among those

**TABLE 3** Frequency distribution of marginal bone level (MBL) changes (number [%]) after treatment

**TABLE 4** Factors associated with disease resolution at 12 months

	Crude model			Adjusted multivariate model		
	OR	95% CI	<i>p</i> value	OR	95% CI	<i>p</i> value
Age (years)						
<50	Reference					
≥50	1.0	0.1–9.8	0.978			
Gender						
Male	Reference					
Female	1.1	0.2–6.7	0.932			
Smoking						
Never or former smokers	Reference					
Smokers	2.1	0.3–13.0	0.420			
Position						
Anterior (I/C)	Reference					
Premolar	0.5	0.0–6.1	0.621			
Molar	0.5	0.1–3.7	0.534			
Arch						
Maxilla	Reference					
Mandible	0.5	0.1–3.1	0.489			
Time in function (years)						
<5	Reference			Reference		
≥5	0.2	0.0–1.0	0.050	0.2	0.0–1.6	0.129
Oral hygiene						
Brushing 1–2 times/day	Reference					
Brushing 3 times/day	0.5	0.0–5.9	0.556			
Brushing 3 times/day + interdental hygiene	0.2	0.0–1.3	0.096			
Defect configuration						
Class I defect	Reference			Reference		
Class III defects	7.3	1.1–47.0	0.038	5.7	0.8–39.9	0.080
Mean PD (mm) at baseline						
Mean PD ≤7 mm	Reference					
Mean PD >7 mm	0.4	0.0–4.0	0.447			
Deepest PD (mm) at baseline						
Deepest PD ≤8 mm	Reference					
Deepest PD >8 mm	5.1	0.9–34.2	0.073			
SoP at baseline						
No	Reference					
Yes	0.5	0.1–2.9	0.420			
MBL (mm) at baseline						
MBL ≤5 mm	Reference					
MBL > 5 mm	0.4	0.1–2.4	0.335			
Intercept				0.2	0.0–1.6	0.141

Abbreviations: CI, confidence interval; I/C, incisors and canines; MBL, marginal bone loss; OR, odds ratio; PD, probing depth; SoP, suppuration on probing.

implants with ≥5 years in function (OR = 0.2; 95% CI [0.0; 1.0];  $p = 0.050$ ) (Table 4). On the other hand, it was harder to achieve disease resolution in implants presenting combined defects as compared

to implants presenting just an infra-osseous defect (OR = 7.3; 95% CI [1.1; 47.0];  $p = 0.038$ ). Those implants presenting a site with a probing depth >8 mm at baseline showed a tendency to fail with the

composite outcome for disease resolution (OR = 5.1; 95% CI [0.9; 34.2];  $p = 0.073$ ). When combined in a multivariate regression analysis, no risk or protective factors were significantly associated with disease resolution—though combined defects showed a tendency to correlate with unsuccessful outcomes (Class III defects, OR = 5.7; 95% CI [0.0; 1.6];  $p = 0.080$ ).

## 4 | DISCUSSION

The present prospective clinical and radiographic study on the 1-year outcomes of the treatment of peri-implantitis revealed significant improvements of all the clinical and radiographic parameters after combined surgical therapy (implantoplasty plus filling of infrabony defects with synthetic hydroxyapatite) together with the use of a piperacillin/tazobactam 100/12.5 mg solution (impregnating the implant, the synthetic hydroxyapatite, and the membrane). Notably, 86% of the peri-implantitis lesions achieved disease resolution after 1 year of follow-up, as evidenced by the absence of BoP, PPD  $\leq 5$  mm, and bone level changes  $\leq 0.5$  mm.<sup>7</sup> However, some features were identified as possible indicators of poorer treatment response, such as the time in function (less time being associated to poorer response), the presence of deep pockets at baseline or the defect morphology, with combined defects being more prone to yield an unsuccessful outcome than pure infra-osseous defects.

Different protocols using different devices (eg, curettes, ultrasound, air-polishing devices, lasers, etc.) or antimicrobials (eg, metronidazole, minocycline, doxycycline, chlorhexidine, etc.) have been proposed for both the nonsurgical and surgical treatment of peri-implantitis.<sup>21,22</sup> On considering the results of nonsurgical therapy, the data fail to provide predictable protocols irrespectively of the decontamination method used.<sup>23</sup> For this reason, surgical approaches have been proposed, especially for more advanced and complex defects.<sup>24</sup>

The choice of the type of surgical protocol may be based on the peri-implant defect configuration. Since around 80% of the defects have been seen to have an infra-osseous and a supra-osseous component,<sup>12</sup> the combined surgical approach has been proposed.<sup>14</sup> This technique consists of combining implantoplasty of the supra-osseous component and/or the buccal or lingual dehiscence together with reconstruction of the infra-osseous component of the defect using a bone substitute and a resorbable membrane. The results after 7 years of follow-up with this technique showed that 79% out of 15 patients achieved disease resolution.<sup>25</sup> The external validity of this therapeutic modality has been confirmed by another research group<sup>26</sup> that evaluated 11 patients with 11 dental implants presenting peri-implantitis. The authors used a similar approach allowing for transmucosal healing. After 12 months, and in agreement with the results of the present study, disease resolution was achieved in 82% of the implants.

Peri-implantitis represents a heterogeneous mixed infection including periodontopathic microorganisms, uncultivable asaccharolytic anaerobic gram-positive rods, other uncultivable gram-negative rods and, rarely, opportunistic microorganisms such as enteric rods and *Staphylococcus*

*aureus*.<sup>27</sup> These complex bacterial communities may challenge biofilm removal. In this sense, mechanical protocols to clean the exposed implant surface have some limitations.<sup>28</sup> Therefore, the adjunctive use of antimicrobials has been proposed to enhance implant decontamination and treatment response.<sup>29</sup>

Among the different antimicrobial therapies, the adjunctive use of systemic antibiotics has been evaluated. Carcuac and colleagues<sup>7</sup> carried out a randomized clinical trial involving 100 patients subjected to surgical treatment of peri-implantitis, dividing them into four groups: systemic antibiotic therapy (amoxicillin 750 mg/12 h) combined with chlorhexidine; systemic antibiotic therapy without chlorhexidine; chlorhexidine without antibiotic therapy; and neither antibiotics nor antiseptics. After 12 months, the overall treatment success rate was 45%, showing a benefit of antibiotics in patients presenting rough implants. However, the 3-year follow-up from the same investigation revealed that the treatment success rate decreased to 33% of all treated implants, suggesting that the potential benefits of systemic antibiotics might not be sustained over the long term.<sup>30</sup> Moreover, the use of chlorhexidine had no impact at all on treatment success. On considering the success rate in the present study (86%) using the same criteria, we hypothesize that this important difference in results may be due to the fact that the topical application of chlorhexidine may be less effective than the topical application of antibiotics. Indeed, in a published study where the intraosseous component of the defect was filled with a mixture of 50% of a particulate mineralized cancellous allograft impregnated with vancomycin and 50% impregnated with tobramycin, a radiographic defect fill of  $86.99 \pm 18.2\%$  was achieved—suggesting that the local application of antibiotics could improve the outcome.<sup>16</sup>

Apart from the possible benefits of antibiotics, we need to bear in mind that bacterial resistances may appear, especially when using the most common antibiotic agents. Rams and colleagues<sup>31</sup> cultured samples from 120 patients with peri-implantitis and analyzed their susceptibility to the following antibiotics: doxycycline, amoxicillin, metronidazole, and clindamycin. The results showed that 46.7% of the patients presented bacterial resistance to clindamycin, 39.2% to amoxicillin, 25% to doxycycline, and 21.7% to metronidazole. In sum, 71.7% of the patients with peri-implantitis had pathogens showing in vitro resistance to one or more of the studied antibiotics.

Piperacillin is a broad-spectrum semisynthetic penicillin that exerts its bactericidal action by inhibiting cell wall and septal synthesis. Tazobactam is a betalactam antibiotic that acts by inhibiting numerous  $\beta$ -lactamases that often produce resistance to penicillin. Tazobactam thus expands the antibiotic spectrum of piperacillin to cover a broad range of  $\beta$ -lactamase producing bacteria, including gram-positive and gram-negative aerobes and anaerobes.<sup>32</sup> Interestingly, when combining piperacillin and tazobactam, none of the isolated bacteria from 16 patients with odontogenic infections affecting multiple maxillofacial and neck regions (accompanied by laboratory signs of sepsis) presented any antibiotic resistance. Indeed, early treatment with this combination of antibiotics is the preferred choice as first-line therapy in cellulitis of odontogenic origin.<sup>33</sup> This is the reason why we hypothesized that the topical use of piperacillin and



tazobactam 100/12.5 mg as part of surface decontamination could exert a positive effect upon the peri-implantitis treatment outcome. Moreover, submucosal irrigation with this antibiotic solution was performed 1 week before the operation with the aim of improving the inflammatory condition of the peri-implant tissues prior to reconstructive surgery. This is in line with a case report by Kim and colleagues,<sup>34</sup> in which the surgical treatment of peri-implantitis was carried out in two phases. The first phase involved access surgery consisting of raising a flap to remove the granulation tissue, followed by the application of 2% chlorhexidine for 5 min and the use of microspheres containing minocycline hydrochloride. In the second phase, 4 weeks later, reconstructive surgery was carried out with the placement of a xenograft and collagen membrane. After a follow-up period of 30 months, a radiographic defect fill of 7 mm was observed.

It is important to highlight that an attempt was made to explore factors associated with treatment response. We found time in function to be positively correlated with disease resolution. In fact, the more years in function, the better the treatment outcomes. We could hypothesize that the sooner peri-implantitis starts, the greater susceptibility there is and, therefore, a poorer treatment response could be expected. Moreover, implants with initial deep pockets of >8 mm showed a tendency to achieve less treatment success, which is in line with the study by Serino and Turri,<sup>35</sup> who reported that implants with initial PPD  $\geq$ 7 mm had greater chances of being extracted 2 years after surgery. Finally, combined type III defects showed a 7-fold lesser probability of achieving disease resolution, which is in line with a study in which pure infra-osseous defects achieved twice the clinical attachment gain and BoP reduction as compared to combined defects.<sup>36</sup>

The analysis of radiographic outcomes is a routine procedure in many studies. It should be noted that evidence of true bone regeneration can only be confirmed histologically. If the evaluation of histological outcomes to assess reosseointegration is not feasible in patients, the use of a composite outcome combining radiographic and clinical outcomes has been suggested. Therefore, the achievement of radiographic defect fill, together with the absence of an increased pocket depth and the absence of mucosal inflammation has been associated with successful regenerative treatment of peri-implantitis lesions.<sup>37</sup>

It is important to acknowledge two main limitations of our series. The first is related to the study design. The absence of a control group prevented us from evaluating the real impact of the local antibiotic used in the present clinical research, which should be established in the context of randomized clinical trials. The second main limitation is related to the short follow-up period involved. It is important to conduct long-term studies to evaluate the impact of supportive therapy (professional maintenance and patient plaque control measures) upon the outcomes after the combined surgical treatment of peri-implantitis. Moreover, it should be noted that the ability to identify risk/protective factors through regression analysis was compromised by the low number of implants ( $n = 6$ ; 14%) in which disease resolution was not achieved. Nevertheless, to the best of our knowledge, this is the first study to evaluate the treatment of peri-implantitis with this local antibiotic.

## 5 | CONCLUSIONS

Taking into account the limitations of this proof of principle study, it can be concluded that the combined surgical approach together with the application of piperacillin/tazobactam as surface decontamination method, may constitute a suitable treatment option to arrest peri-implant inflammation and bone loss in implants affected by peri-implantitis. Randomized clinical trials are needed to confirm whether the use of this local antibiotic provides superior outcomes versus surgery alone.

### ACKNOWLEDGMENTS

The authors gratefully acknowledge the help of Ms. María Jesus Baeza (librarian of Arnau de Vilanova Hospital, Valencia, Spain). No funding or material support was received for this study.

### CONFLICT OF INTEREST

The authors declare no conflicts of interest.

### AUTHOR CONTRIBUTIONS

**Iria González Regueiro:** data collection, data analysis/interpretation, approval of article. **Natalia Martínez Rodríguez:** critical revision of article, approval of article. **Cristina Barona Dorado:** data collection, data analysis/interpretation, critical revision of article, approval of article. **Ignacio Sanz-Sánchez:** data analysis/interpretation, drafting article, critical revision of article, approval of article. **Eduardo Montero:** data analysis/interpretation, drafting article, critical revision of article, approval of article. **Javier Ata-Ali:** concept/design, data analysis/interpretation, drafting article, critical revision of article, approval of article. **Fernando Duarte:** critical revision of article, approval of article. **José María Martínez-González:** concept/design, data collection, data analysis/interpretation, drafting article, critical revision of article, approval of article.

### DATA AVAILABILITY STATEMENT

The data that support the findings of this study are available on request from the corresponding author. The data are not publicly available due to privacy or ethical restrictions.

### ORCID

Natalia Martínez Rodríguez  <https://orcid.org/0000-0002-4395-5953>

Cristina Barona Dorado  <https://orcid.org/0000-0003-0966-3276>

Ignacio Sanz-Sánchez  <https://orcid.org/0000-0002-3698-4772>

Eduardo Montero  <https://orcid.org/0000-0003-2525-8529>

Javier Ata-Ali  <https://orcid.org/0000-0001-6542-5710>

José María Martínez-González  <https://orcid.org/0000-0002-6192-3656>

### REFERENCES

1. Renvert S, Persson GR, Piri FQ, Camargo PM. Peri-implant health, peri-implant mucositis, and peri-implantitis: case definitions and diagnostic considerations. *J Periodontol*. 2018;89(Suppl 1):S304-S312.

2. Berglundh T, Armitage G, Araujo MG, et al. Peri-implant diseases and conditions: consensus report of workgroup 4 of the 2017 world workshop on the classification of periodontal and peri-implant diseases and conditions. *J Periodontol*. 2018;89(Suppl 1):S313-S318.
3. Derks J, Tomasi C. Peri-implant health and disease. A systematic review of current epidemiology. *J Clin Periodontol*. 2015;42(Suppl 16):S158-S171.
4. Salvi GE, Cosgarea R, Sculean A. Prevalence and mechanisms of peri-implant diseases. *J Dent Res*. 2017;96(1):31-37.
5. Rodrigo D, Sanz-Sánchez I, Figuero E, et al. Prevalence and risk indicators of peri-implant diseases in Spain. *J Clin Periodontol*. 2018;45(12):1510-1520.
6. Ata-Ali J, Candel-Martí ME, Flichy-Fernández AJ, Peñarrocha-Oltra D, Balaguer-Martínez JF, Peñarrocha DM. Peri-implantitis: associated microbiota and treatment. *Med Oral Patol Oral Cir Bucal*. 2011;16(7):e937-e943.
7. Carcuac O, Derks J, Charalampakis G, Abrahamsson I, Wennström J, Berglundh T. Adjunctive systemic and local antimicrobial therapy in the surgical treatment of peri-implantitis: a randomized controlled clinical trial. *J Dent Res*. 2016;95(1):50-57.
8. Sanz M, Chapple IL, Periodontology WGotVEWo. Clinical research on peri-implant diseases: consensus report of Working Group 4. *J Clin Periodontol*. 2012;39(Suppl 12):202-206.
9. Khoury F, Keeve PL, Ramanauskaitė A, et al. Surgical treatment of peri-implantitis – consensus report of working group 4. *Int Dent J*. 2019;69(Suppl 2):18-22.
10. Rocuzzo M, Layton DM, Rocuzzo A, Heitz-Mayfield LJ. Clinical outcomes of peri-implantitis treatment and supportive care: a systematic review. *Clin Oral Implants Res*. 2018;29(Suppl 16):331-350.
11. Serino G, Wada M, Mameno T, Renvert S. Two- and ten-year follow-up of patients responding and non-responding to the surgical treatment of peri-implantitis: a retrospective evaluation. *Clin Oral Implants Res*. 2021;32:410-421.
12. Schwarz F, Herten M, Sager M, Bieling K, Sculean A, Becker J. Comparison of naturally occurring and ligature-induced peri-implantitis bone defects in humans and dogs. *Clin Oral Implants Res*. 2007;18(2):161-170.
13. Schwarz F, John G, Mainusch S, Sahm N, Becker J. Combined surgical therapy of peri-implantitis evaluating two methods of surface debridement and decontamination. A two-year clinical follow up report. *J Clin Periodontol*. 2012;39(8):789-797.
14. Schwarz F, Sahm N, Iglhaut G, Becker J. Impact of the method of surface debridement and decontamination on the clinical outcome following combined surgical therapy of peri-implantitis: a randomized controlled clinical study. *J Clin Periodontol*. 2011;38(3):276-284.
15. Mercado F, Hamlet S, Ivanovski S. Regenerative surgical therapy for peri-implantitis using deproteinized bovine bone mineral with 10% collagen, enamel matrix derivative and doxycycline—a prospective 3-year cohort study. *Clin Oral Implants Res*. 2018;29(6):583-591.
16. Nart J, de Tapia B, Pujol À, Pascual A, Valles C. Vancomycin and tobramycin impregnated mineralized allograft for the surgical regenerative treatment of peri-implantitis: a 1-year follow-up case series. *Clin Oral Investig*. 2018;22(6):2199-2207.
17. Rocuzzo M, Fierravanti L, Pittoni D, Dalmaso P, Rocuzzo A. Implant survival after surgical treatment of peri-implantitis lesions by means of deproteinized bovine bone mineral with 10% collagen: 10-year results from a prospective study. *Clin Oral Implants Res*. 2020;31(8):768-776.
18. Sukumar S, Martin FE, Hughes TE, Adler CJ. Think before you prescribe: how dentistry contributes to antibiotic resistance. *Aust Dent J*. 2020;65(1):21-29.
19. Monje A, Pons R, Rocuzzo A, Salvi GE, Nart J. Reconstructive therapy for the management of peri-implantitis via submerged guided bone regeneration: a prospective case series. *Clin Implant Dent Relat Res*. 2020;22(3):342-350.
20. Jepsen S, Berglundh T, Genco R, et al. Primary prevention of peri-implantitis: managing periimplant mucositis. *J Clin Periodontol*. 2015;42(Suppl 16):S152-S157.
21. Figuero E, Graziani F, Sanz I, Herrera D, Sanz M. Management of peri-implant mucositis and peri-implantitis. *Periodontol 2000*. 2014;66(1):255-273.
22. Rocuzzo A, Stähli A, Monje A, Sculean A, Salvi GE. Peri-implantitis: a clinical update on prevalence and surgical treatment outcomes. *J Clin Med*. 2021;10(5):1107.
23. Suárez-López Del Amo F, Yu SH, Wang HL. Non-surgical therapy for peri-implant diseases: a systematic review. *J Oral Maxillofac Res*. 2016;7(3):e13.
24. Heitz-Mayfield LJ, Mombelli A. The therapy of peri-implantitis: a systematic review. *Int J Oral Maxillofac Implants*. 2014;29(Suppl):325-345.
25. Schwarz F, John G, Schmucker A, Sahm N, Becker J. Combined surgical therapy of advanced peri-implantitis evaluating two methods of surface decontamination: a 7-year follow-up observation. *J Clin Periodontol*. 2017;44(3):337-342.
26. Matarasso S, Iorio Siciliano V, Aglietta M, Andreuccetti G, Salvi GE. Clinical and radiographic outcomes of a combined resective and regenerative approach in the treatment of peri-implantitis: a prospective case series. *Clin Oral Implants Res*. 2014;25(7):761-767.
27. Lafaurie GI, Sabogal MA, Castillo DM, et al. Microbiome and microbial biofilm profiles of peri-implantitis: a systematic review. *J Periodontol*. 2017;88(10):1066-1089.
28. Keim D, Nickles K, Dannewitz B, Ratka C, Eickholz P, Petsos H. In vitro efficacy of three different implant surface decontamination methods in three different defect configurations. *Clin Oral Implants Res*. 2019;30(6):550-558.
29. Schwarz F, Becker K, Sager M. Efficacy of professionally administered plaque removal with or without adjunctive measures for the treatment of peri-implant mucositis. A systematic review and meta-analysis. *J Clin Periodontol*. 2015;42(Suppl 16):S202-S213.
30. Carcuac O, Derks J, Abrahamsson I, Wennström JL, Petzold M, Berglundh T. Surgical treatment of peri-implantitis: 3-year results from a randomized controlled clinical trial. *J Clin Periodontol*. 2017;44(12):1294-1303.
31. Rams TE, Degener JE, van Winkelhoff AJ. Antibiotic resistance in human peri-implantitis microbiota. *Clin Oral Implants Res*. 2014;25(1):82-90.
32. Agencia Española de Medicamentos y Productos Sanitarios. Ficha técnica piperacilina/tazobactam. 2021, January. Available from: <http://www.aemps.gob.es/>
33. Weise H, Naros A, Weise C, Reinert S, Hoefert S. Severe odontogenic infections with septic progress – a constant and increasing challenge: a retrospective analysis. *BMC Oral Health*. 2019;19(1):173.
34. Kim JE, Kim HY, Huh JB, Lee JY, Shin SW. A two-stage surgical approach to the treatment of severe peri-implant defect: a 30-month clinical follow-up report. *J Oral Implantol*. 2014;40(3):299-305.
35. Serino G, Turri A. Outcome of surgical treatment of peri-implantitis: results from a 2-year prospective clinical study in humans. *Clin Oral Implants Res*. 2011;22(11):1214-1220.
36. Schwarz F, Sahm N, Schwarz K, Becker J. Impact of defect configuration on the clinical outcome following surgical regenerative therapy of peri-implantitis. *J Clin Periodontol*. 2010;37(5):449-455.
37. Renvert S, Roos-Jansåker AM, Persson GR. Surgical treatment of peri-implantitis lesions with or without the use of a bone substitute—a randomized clinical trial. *J Clin Periodontol*. 2018;45(10):1266-1274.

**How to cite this article:** González Regueiro I, Martínez Rodríguez N, Barona Dorado C, et al. Surgical approach combining implantoplasty and reconstructive therapy with locally delivered antibiotic in the treatment of peri-implantitis: A prospective clinical case series. *Clin Implant Dent Relat Res*. 2021;1-10. doi:10.1111/cid.13049