

implants

international magazine of oral implantology

research

Professional implant management

case report

Combining standard and ultrashort implants in full-mouth rehabilitation

case report

Interproximal root spreading for narrow implant placement



Mandibular dentigerous cyst

Enucleation and bone reconstruction

Drs Fernando Duarte & Carina Ramos, Portugal

The **dentigerous or follicular cyst** is the most common type of developmental odontogenic cyst and the second most common among all that occur in the jaws, representing about 20% of all cysts.^{1,2} By definition, a dentigerous cyst is attached to the tooth cervix (cemento-enamel junction) and encloses the crown of the unerupted tooth. It is a benign lesion associated with the odontogenic epithelium of the crown of an unerupted tooth and originates from the separation of the follicle around the crown of the tooth in question, forming a cavity bounded by the reduced enamel epithelium and the tooth enamel, which is filled with cystic fluid.³ As with other cysts, expansion of a dentigerous cyst is related to epithelial proliferation, release of bone-resorbing factors and an increase in cyst fluid osmolality.

Aetiology and pathogenesis

Although its aetiopathogenesis is not fully known, it is believed that epithelial proliferation around a fluid-filled cavity grows continuously by osmotic pressure over an extended period, as long as the tooth does not erupt.³ If this pressure is removed by the tooth erupting, the cyst will no longer be a pathological entity.³

Histopathology

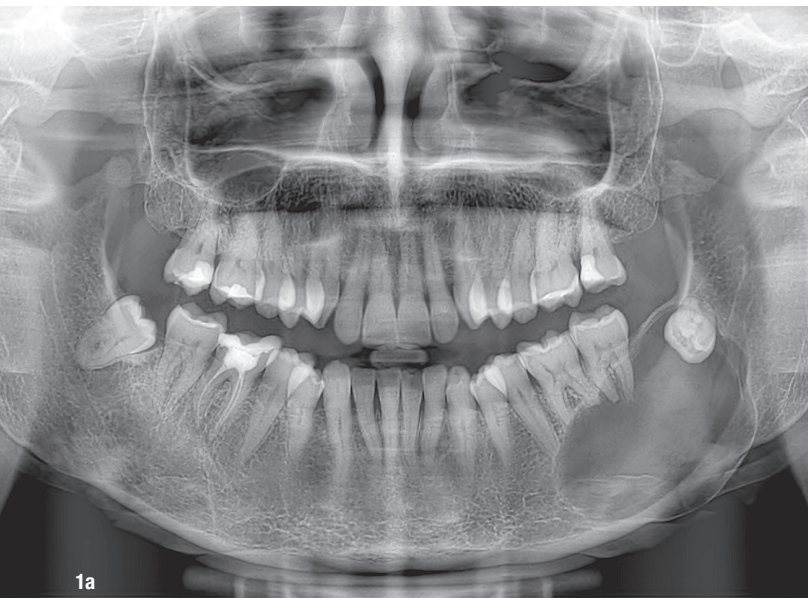Histologically, the characteristics of dentigerous cyst are variable. If it is not inflamed, it has a loose and thin connective tissue capsule, covered by non-keratinised epithelial cells, composed of two or three layers of flat or cuboidal cells. When there is a secondary infection present, the connective tissue is denser and there is variable infiltration of chronic inflammatory cells. The lining epithelium may show variable levels of hyperplasia, developing epithelial ridges with more striking scaly characteristics.¹

Differential diagnosis

Differential diagnosis of pericoronal radiolucency should include odontogenic keratocyst, ameloblastoma and other odontogenic tumours. Ameloblastic transformation of a dentigerous cyst lining should also be part of the differential diagnosis. Adenomatoid odontogenic tumour would be a further consideration with anterior pericoronal radiolucencies, and ameloblastic fibroma would be a possibility for lesions occurring in the posterior of the jaws of young patients.³

Clinical features

Dentigerous cyst occurs predominantly in the first three decades of life, has a predilection for the male sex and affects more Caucasian individuals. Although this pathology may occur in any unerupted tooth, the teeth most frequently affected are the mandibular third molars, maxillary canines and mandibular premolars.^{1,4} The occurrence in primary dentition is extremely rare.⁵ Clinically, these lesions are, in most cases, of slow and asymptomatic growth; however, they can grow considerably and cause expansion of the cortical bone, facial deformation, impaction or displacement of teeth and adjacent structures, paraesthesia and discomfort.⁶ They may be associated with some syndromes, when they present in multiple or bilateral forms, such as Maroteaux-Lamy syndrome and cleidocranial dysplasia.⁶ Radiographically, in most cases, dentigerous cyst appears as a radiolucent unilocular cavity with a well-defined sclerotic margin, involving the crown of an unerupted tooth, starting from the cemento-enamel junction, although multilocular aspects can also occur in large lesions.^{7,8} While a normal dental



1a

Fig. 1a: Initial dental panoramic tomogram.

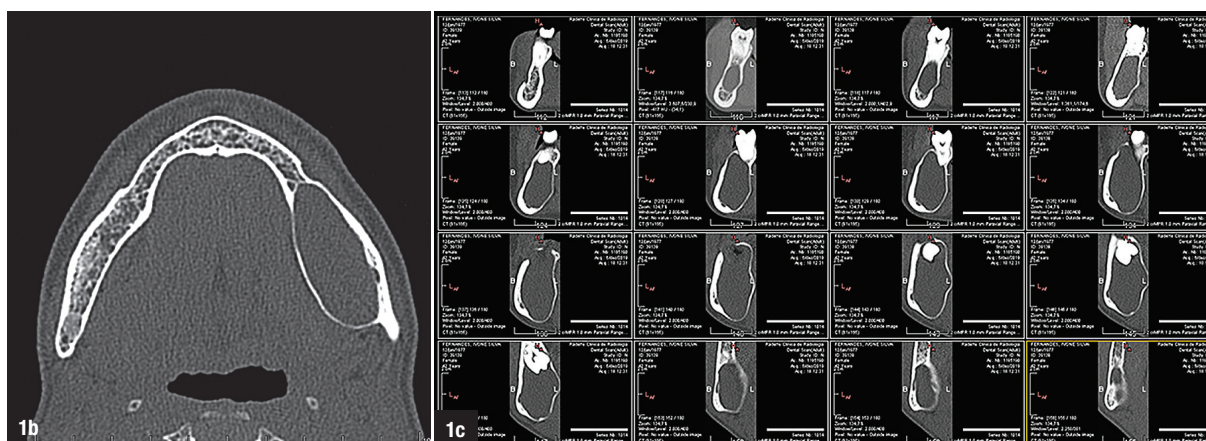


Fig. 1b: Initial CT sagittal section. **Fig. 1c:** Initial CT cross section.

follicle has 3–4 mm of space between the tooth and its margin, this cyst can be suspected when this space is larger than 5 mm.^{1,8} When located in the mandible, this cyst can cause the displacement of the mandibular canal, the resorption of the wall of this canal, the root resorption of adjacent teeth or even pathological mandibular fracture.^{9,10}

Treatment options

Marsupialisation and enucleation are the classic techniques for the treatment of dentigerous cyst and may be associated.^{7,8} Decompression, using a decompression device, is an option, when followed by enucleation, for the treatment of large cysts. However, the criteria for choosing one of these modalities are not clearly defined, owing to the lack of exhaustive studies and adequate follow-ups.¹¹ As accepted criteria for diagnosis and treatment, the size of the cyst, the age of the patient, the teeth involved and the involvement of anatomical structures must be taken into account.¹ The treatment modality to be chosen will depend on the clinical and radiographic characteristics in question. Lesion aspiration should be performed in all cases, as radiographically similar lesions can be odontogenic tumours or vascular lesions and not cysts as expected, the detection of fluid inside the lesion being a major indication of cyst.^{12–14}

Incisional biopsy must then necessarily be performed to differentiate the type of cyst, as other lesions, such as odontogenic keratocysts and unicystic ameloblastoma, may have similar clinical and radiographic characteristics; however, they are more aggressive locally, requiring more extensive treatment and thus sacrifice of neurovascular tissue, bone and adjacent teeth.^{11, 12, 15} The prognosis of dentigerous cyst is favourable and has a low recurrence rate (3.7%); even so, the follow-up must be strict.¹⁰ Enucleation of the cyst and extraction of the associated unerupted tooth are performed in about 85% of cases and are the treatment of choice for small lesions with a

safe distance from anatomical structures, such as the inferior alveolar nerve.^{1,12} In these patients, this is indicated if the unerupted tooth is considered useless for masticatory or aesthetic function or there is a lack of clinical space for its eruption.^{10, 11, 14} In dentigerous cysts of third mandibular molars, the larger the cyst, the greater the risk of nerve injury and weakening of the mandibular angle caused by the surgery. Therefore, in these cases, the most appropriate therapeutic modality would be decompression followed by enucleation, after reducing the size of the lesion.^{16–18}

Bone reconstruction

The two-stage treatment is time-consuming, uncomfortable for patients and requires frequent check-ups. One-stage cystectomy of large cysts with watertight closure of the postoperative bone cavity predisposes to complications. Moreover, the weakened bone structure is prone to fractures in the postoperative period. This is why there is particular interest in filling the bone cavities with autografts or bone substitutes.

Clinical case

A 43-year-old Caucasian female patient attended the oral and maxillofacial surgery consultation at Clitrofa medical centre in Trofa in Portugal to assess extraction of teeth #38 and 48. She was asymptomatic, without paraesthesia, hypoaesthesia or other complaints. Anamnesis established that there were no allergies or use of medication. On extra-oral clinical examination, no abnormality was observed. On intra-oral physical examination, a slight bulging of the cortical bone was noted in the region of the left external oblique line adjacent to tooth #37, but no chromatic alteration in the oral mucosa. The dental panoramic tomogram showed a unilocular, well-defined, homogeneous radiotransparent area surrounding the dental crown of the included tooth #38, extending to the tooth #35 region (Fig. 1a). In the coronal, sagittal and

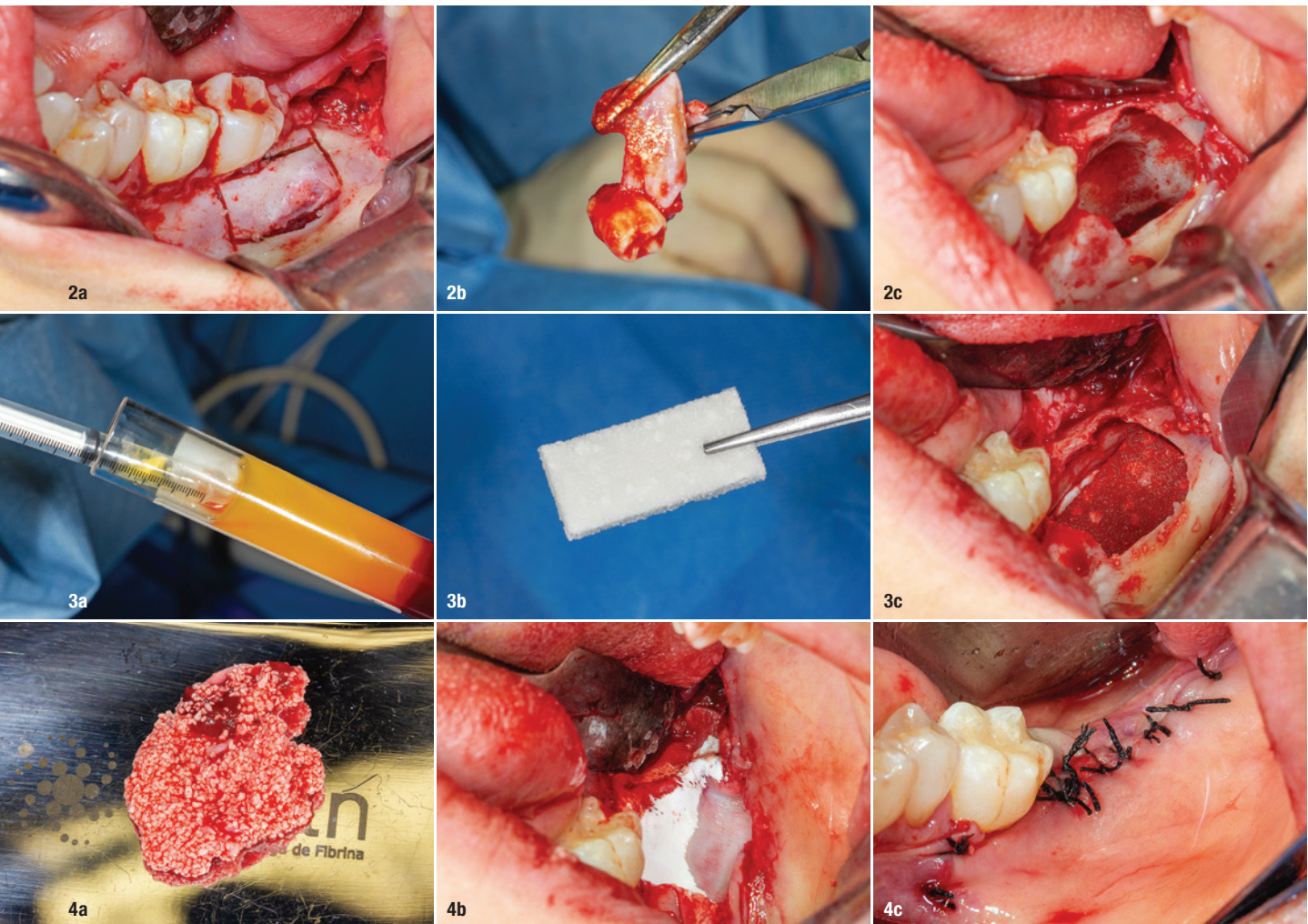


Fig. 2: Osteotomy with piezoelectric surgery (a), cystic capsule with impacted tooth 38 (b), intraoperative image of the cystic cavity (c). **Fig. 3:** Platelet-rich fibrin (a), CERASORB® Foam used to protect the inferior alveolar nerve (b), intraoperative image of inferior layer of bone reconstruction (c). **Fig. 4:** Sticky bone for cystic cavity reconstruction (a), Osgide® resorbable membrane covering complete area of bone reconstruction (b), intraoperative image after suturing (c).

axial sections of the CT scan, it could be seen that the lesion was in close contact with the mandibular canal and there was cortical bulging (Figs. 1b & c).

As initial options for diagnosis, the possibilities of odontogenic keratocysts, unicystic ameloblastoma, adenomatoid odontogenic tumour and dentigerous cyst were considered. Aspiration puncture was performed under local anaesthesia, producing a small amount of light-yellow liquid and thus confirming the cystic nature of the lesion and working as decompression to reduce the lesion size. Endodontic treatment of tooth #36 was performed prior to surgical intervention. The patient was operated on under general anaesthesia, with nasal intubation. An intra-oral incision was made in the left retro-molar region that extended to the canine region, where a discharge incision was made. The osteotomy for access to the cystic cavity was performed by piezoelectric surgery. Based on 3D control of ultrasonic microvibrations, a micrometric and selective cut is allowed, under good

visibility (cavitation effect) that results in minimal damage to soft tissue and nervous structures (Fig. 2a).¹⁹ The equipment used was the VarioSurg3 (NSK). The cystic capsule was excised together with the extraction of included tooth #38 and tooth #37 (Fig. 2b). The remaining cavity was cleaned with saline solution, keeping the lower border of the mandible intact (Fig. 2c).

Bone regeneration was performed with CERASORB® M (curasan) in granule and foam form combined with fibrin and Osgide® resorbable membrane (curasan). CERASORB® M is a resorbable and pure-phase beta-tricalcium phosphate ceramic for implantation filling, binding and reconstruction of bone defects, as well as bone fusion in the entire skeletal system. The granules have a polygonal shape, and owing to the open intercommunicating multi-porosity composed of micro-, meso- and macropores (about 65%), the radiopacity is lower and absorption is effected faster. Over months in contact with the vital bone, the material is resorbed by

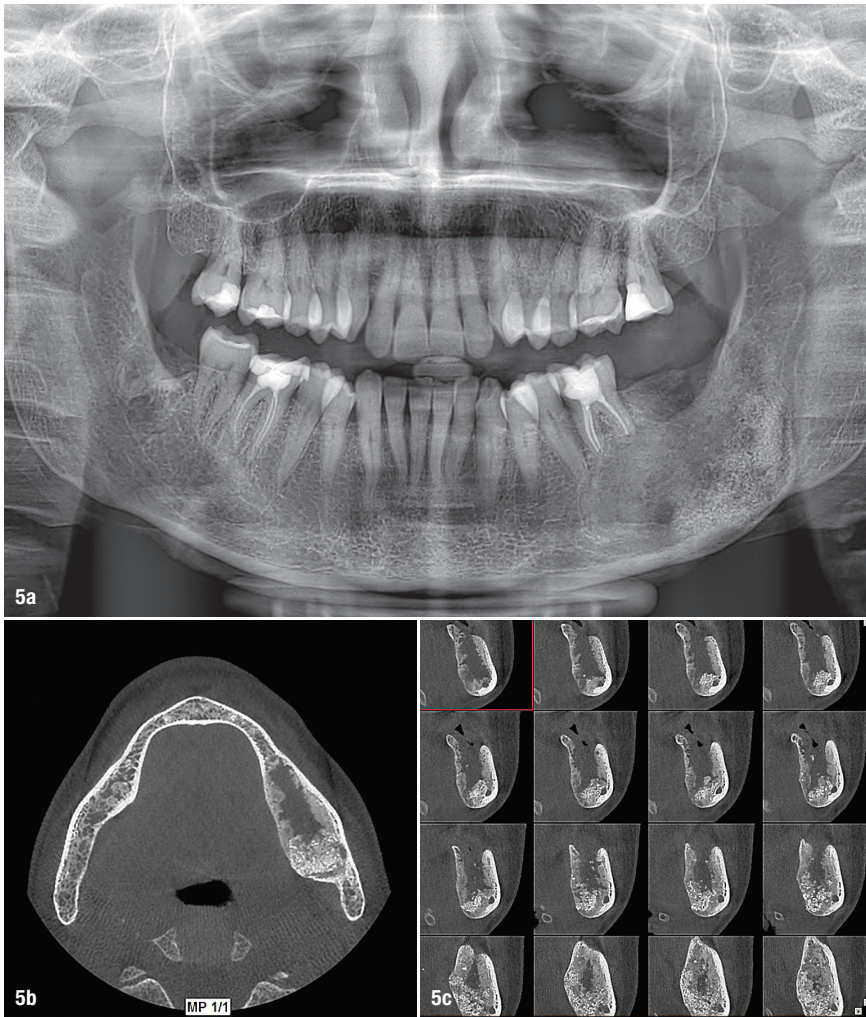


Fig. 5: Final dental panoramic tomogram (a), final CT sagittal section (b), final CT cross section (c).

the body and simultaneously replaced by autologous bone tissue. As a synthetic and bioactive ceramic material, CERASORB® M has no local or systemic toxicity and no risk of allergic reaction. CERASORB® M is radiopaque and can be used in granule, paste and foam form.²⁰ The use of autologous platelet-rich fibrin (PRF) in the grafting process offers beneficial characteristics in the modulation of the inflammatory response, immune response and tissue repair, tissue reorganisation and angiogenesis (Fig. 3a).²¹ The association of PRF with mineral biomaterials (I-PRF) facilitates handling and application and allows immediate adhesion to the receiving bed (Figs. 3b & c).²¹

The inferior layer of bone reconstruction was performed with CERASORB® Foam soaked with PRF in an attempt to protect

the inferior alveolar nerve integrity and strengthen the lower border of the mandible. The superior reconstruction layer was done with CERASORB® M granules combined with PRF, creating what is described as sticky bone. Sticky bone provides stabilisation of the bone graft and is easy to manipulate and therefore accelerates tissue healing and minimises bone loss during the healing period (Fig. 4a). An Osgide® resorbable membrane was used to cover the bone reconstruction. Osgide is a bioresorbable barrier membrane for use in guided tissue regeneration and guided bone regeneration. The membrane creates a protective environment for bone regeneration in the defect area and supports osteoneogenesis by presenting a barrier to the infiltration (migration) of soft tissue and promoting the growth of osteogenic cells in the bony defect



Shortest Implants – Longest History.

Think Short!

For more than 30 years Bicon® short implants are unchanged in clinical use.

According to the 11th European Consensus Conference (EuCC) 2016 in Cologne, provided the specific treatment parameters are observed, the use of short, angulated or diameter-reduced implants in sites with reduced bone volume can be a reliable treatment option, given the risks associated with the use of standard-dimension implants in combination with augmentation procedures.

For more Information:

Bicon Europe Ltd.

Dietrichshoehe 2

55491 Buechenbeuren

Germany

Phone +49 (0)6543 818200

germany@bicon.com

www.bicon.de.com



bicon
DENTAL IMPLANTS

(Fig. 4b). Suturing was performed with simple stitches using non-resorbable thread (silk, 4/0; Fig. 4c).

The patient underwent systemic antibiotic, analgesic and anti-inflammatory therapy for eight days. In postoperative care, the patient was instructed to maintain strict oral hygiene. The material obtained from the cystic cavity was sent for pathological examination, and the findings were islands of odontogenic epithelium remains scattered in the fibrous connective tissue capsule, composed of three layers of flattened, non-keratinised cells. These findings confirmed the diagnosis of dentigerous cyst. At the time of writing, the patient was in the postoperative period of 12 months and had shown no hypoaesthesia or any sign of recurrence of the lesion. In the postoperative dental panoramic tomogram (Fig. 5a) and CT scan, there was evidence of bone neo-formation in the area previously occupied by the lesion (Figs. 5b & c).

Discussion

Among the possible treatment techniques for dentigerous cyst, the most suitable for each clinical situation should be evaluated, considering all scenarios for each option.⁷ In the present clinical case, had the treatment been decided on considering only the size of the lesion, enucleation would have been the most appropriate choice associated with the extraction of the impacted tooth #38. Owing to the proximity of the inferior alveolar nerve, decompression followed by cyst enucleation and extraction of the tooth in question was the most reasonable option. This allowed bone regeneration of the cystic cavity, as well as maintenance of nerve integrity. Enucleation is the technique of choice for cysts of smaller dimensions and when there is no involvement of important anatomical structures, since it provides the possibility of a histological study of the lesion.^{1,12} Marsupialisation and decompression with the use of a device should be reserved for clinical cases of extensive dimensions, involving important anatomical structures and increased risk of fracture, as they promote the reduction of intracystic pressure, consequently reducing the size of the lesion.^{7,8,10,11,18} Taking into account this objective of decompression, it was decided in this clinical case to maintain the lesion–oral cavity communication created during the aspiration puncture, which, although reduced, was sufficient to regress the dimensions of the lesion.

Both marsupialisation and decompression are therapeutic modalities also indicated in the period when the bone repair capacity is high and the eruptive power of the teeth is present.^{10,11} Sticky bone is biologically solidified bone grafting material which is entrapped in fibrin network. Sticky bone graft granules are strongly interconnected to each other by the fibrin network. Sticky bone has numerous advantages:

1. It is mouldable, so it adapts well to various shapes of bony defects.
2. Micro- and macro-movement of grafted bone is prevented, so the volume of augmentation is maintained during the healing period. Therefore, the need for block bone and titanium mesh is minimised.
3. Fibrin network entraps platelets and leucocytes to release growth factors, so bone regeneration and soft-tissue growth are accelerated.
4. No biochemical additives are needed to make sticky bone.
5. Fibrin interconnection minimises soft-tissue ingrowth into the sticky bone graft.²¹

Conclusion

Dentigerous cyst is a frequent lesion which, despite being a less aggressive pathology and without clinical symptoms, has the potential to reach large proportions, causing significant movement of teeth. The treatment decision must be based on objective criteria, such as age of the patient, size of the lesion, involvement of relevant anatomical structures, clinical importance of the tooth or teeth associated with the lesion, and risk of bone fracture. It is essential to perform a histopathological examination for the differential diagnosis, ruling out other types of lesions with similar clinical and radiographic characteristics, as well as to perform annual postoperative radiographic monitoring.



about the author



Dr Fernando Duarte is a Portugal-based dentist who specialises in oral surgery. He holds a postgraduate qualification in oral and maxillofacial surgery and a master's degree in oral and maxillofacial surgery from Eastman Dental Institute at University College London in the UK. Dr Duarte is the CEO and clinical director of the Clitrofa medical centre in Trofa in Portugal.

contact

Dr Fernando Duarte

Clitrofa—Centro Médico, Dentário e Cirúrgico
Avenida de Paradela 626
4785-342 Trofa
Portugal
Phone: +351 252 428960
fduarte@clitrofa.com

