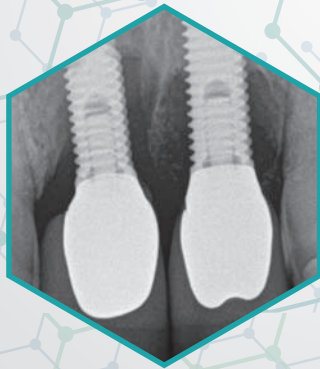


STneDent

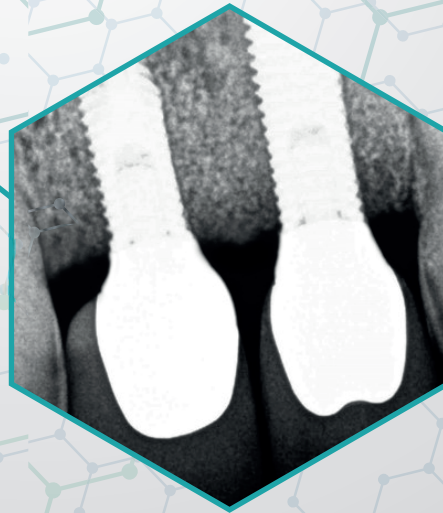
where science meets the dental practice

FROM THEORY TO CLINIC LONG TERM OUTCOME OF A SEVERE PERI-IMPLANTITIS CASE

BEFORE



AFTER



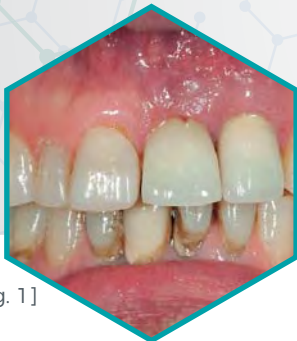FROM THEORY TO CLINIC LONG TERM OUTCOME OF A SEVERE PERI-IMPLANTITIS CASE

Peri-implantitis treatment with **Implacure**

CASE HISTORY

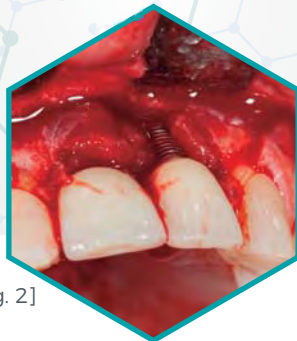
48 year old man with a 6mm+ defect in two implants that had over 6 years in mouth. Strong BoP, no pain, implant stability.

BEGINNING



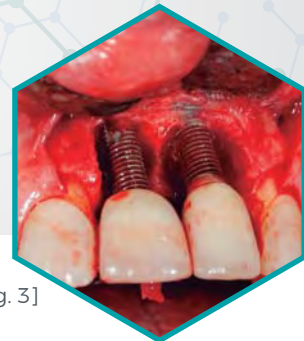[Fig. 1]

Patient observed some decoloration of the gum and complained about daily bleeding. (Fig. 1)
Previous professionals prescribed increased hygiene plus some antibiotics to control the swelling.

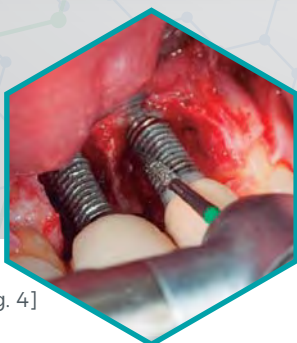

[Fig. 2]

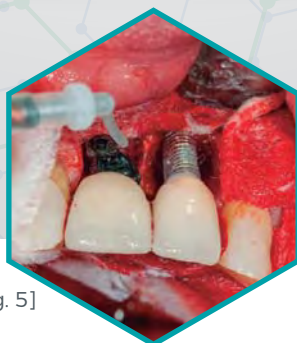Upon opening a huge defect was exposed. (Fig. 2)
Necrosied tissue was removed exposing extensive defects of over 6mm. (Fig. 3)



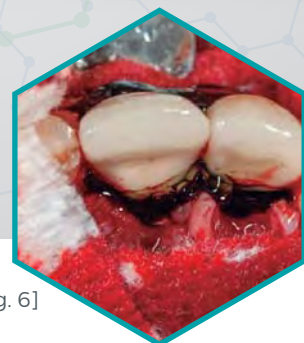[Fig. 3]



[Fig. 4]



[Fig. 5]



[Fig. 6]

Once cleaned we perform a thorough implantoplasty using Implacure's set of burs. When finished we apply our exclusive decontaminant around the exposed surface of the implant.

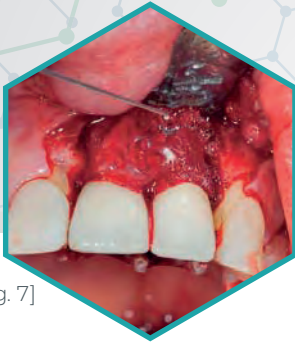DR. FERNANDO DUARTE



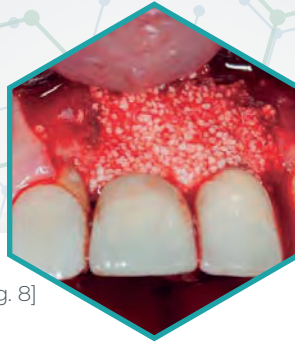"The power of a combined treatment that includes mechanical debridement, a complete disinfection of the implant surface and the surrounding tissues, plus the long term effect of a powerful broad base antibiotic with the regeneration capability of hyaluronic acid allows us to treat the toughest peri-implant cases with success. In Implacure we found a great support to return hope to patients"



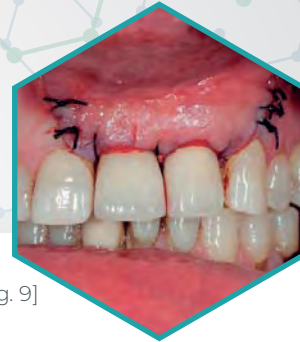LOCAL ANTIBIOTIC LAB APPLICATION AND REGENERATION



[Fig. 7]



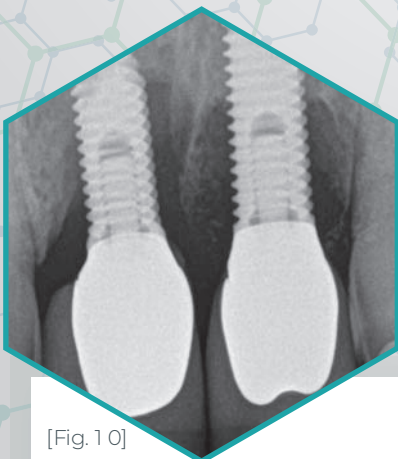
[Fig. 8]



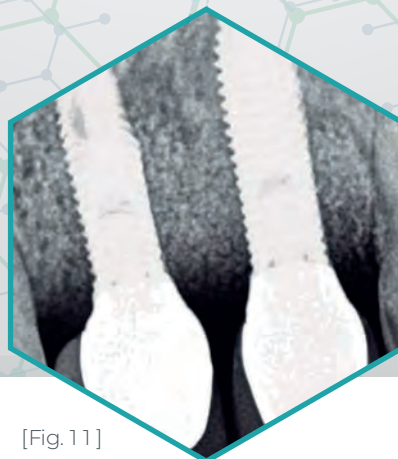
[Fig. 9]

Once removed the disinfectant we applied the local antibiotic (Fig. 7) at the implant surface then we mixed it with the regenerative material, using the hyaluronic acid as a trigger to accelerate recovery. (Fig. 8) Once stabilized we positioned the membrane, also impregnated with Implacure's LAB, and we closed. (Fig. 9)

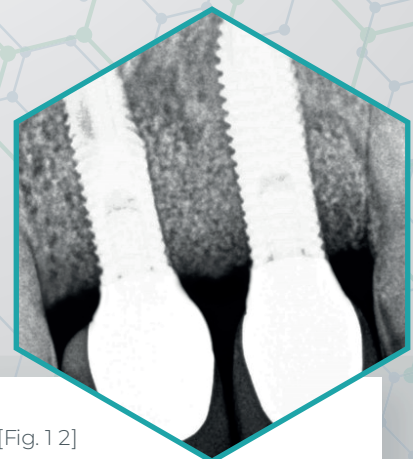
12 MONTHS



[Fig. 10]



[Fig. 11]



[Fig. 12]

After (Fig. 10). Six months after the initial treatment (Fig. 11), strong results were seen. There was no inflammation and no bleeding on probing. (Fig. 12)



- Application of local broad spectrum antibiotic proves to be more effective than those supported with systemic antibiotic. Because there is no irrigation at the implant surface, systemic treatments offer no antimicrobial activity where the infection is, while local antibiotics act from the application^{1,2}.
- Due to the comprehensive treatment protocol, **Implacure** ensures the stoppage of the progression of the peri-implant disease. Moreover, in over 80% of the cases, strong bone regeneration is achieved after one year³.
- The combined action of a powerful, locally applied broad spectrum antibiotic, combined with our hyaluronic acid, stimulates recovery and regeneration⁴.

SCIENTIFIC REFERENCES

- **Local Antibiotic Therapy in the Treatment of Bone and Soft Tissue Infections** Stefanos Tsourvakas, Orthopedic Department, General Hospital of Trikala. Dr Stefan Danilla (Ed.), ISBN: 978-953-307-836-6, InTech.
- **"Evidence based Otitis Media"** Table 28.4 by Richard M. Rosenfeld, Charles D. Bluestone. 2003 BC Decker Inc – Hamilton London, UK.
- **Is it possible to Stop the Progression of Peri-Implantitis?** poster by Dr. Juan Carlos Navarro presented at the Lindhe Symposium, May 2017, Gothenburg University.
- **Implant surgery: treatment with a fluid gel compound with hyaluronic acid and piperacillin plus tazobactam** Giacomo Bartoloni Saint Omer Doctor Os, January 2015.

ABOUT CLITROFA AND DR. FERNANDO DUARTE

MTD

www.medtechdental.com
info@medtechdental.com
+41 78 343 29 80 / +41 61 482 16 16
Lettenweg 132
CH4123 Allschwil
Switzerland

Dr. Fernando Duarte

- Medical Dentist, Specialist in Oral Surgery by OMD.
- MSc in Oral and Maxillofacial Surgery at the Eastman Dental Institute University of London.
- Postgraduate in Oral and Maxillofacial Surgery.
- PhD student Scientific consultant for SIN, MTD, Curasan & Oxford Scientific.

Clitrofa was founded on September 16, 2002. A project that began with about 400 m² Clitrofa expanded, with an area of 3600 m² divided into five intervention areas: Clinic, Laboratory of Prosthodontics, Training, Imaging and Medical Spa. This project comes as an integral option for patients that wish to medical treatments in the area of aesthetic and rehabilitation in oral, facial and bodily terms. Thus becomes an innovative project with the creation of a unique vision; the implementation of the concept of Clitrofa – Medical Dental Hospital. Clitrofa is also renowned for its Education Academy, that has given courses and support to thousands of doctors worldwide.

